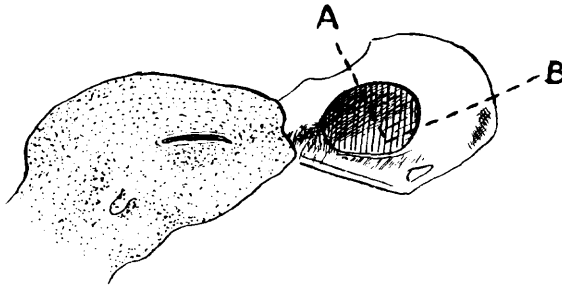


seeds were taken one at a time to a suitable crevice and the fragments of meat were fed to the young.—Helmut C. Mueller, Dept. of Zoology, 205 Wilson Hall, Univ. of North Carolina, Chapel Hill, N. C. 27514.

**Removal of Cranium During Preparation of Study Skins for Later Ossification Studies.** A knowledge of the degree of ossification of the cranium is essential when doing age criteria studies for many passerines. The cranium condition, if recorded, is usually marked on the specimen label but the degree of ossification is often unknown and the experience and accuracy of the preparator in judging skulls is often questionable. However, the fresh specimen can be prepared as a study skin in the normal manner with the cranium detached and tied to the legs beside the specimen tag for permanent reference.

Figure 1. Cuts made to remove cranium.



The bird is skinned in the usual manner with the skin inverted over the head. The ears, eyes, tongue, base of the skull, and the brain are removed in the normal manner. Now three cuts need to be made to remove the cranium. The first cut (see A in figure 1) is across the roof of the orbits (between the eyes) and the next two cuts (see B in Figure 1) are on a line parallel to the lower mandible through the squamosal bones. The cranium is now free from the skull and should be attached later to the legs of the specimen by pushing threaded needle gently through the side region (squamosal bone) and tying to the legs. While turning the skin right side out over the remaining parts of the skull, two balls of cotton should be held in the normal position of the eyes and a smaller ball of cotton held behind these to replace the cranium that was removed. With a little practice the study skin will turn out as well as one with the cranium intact.

Specimens prepared in this manner will greatly increase our knowledge of the ossification process in passerines and can be extended to other orders so that aging methods may be worked out in later studies.—Gilbert S. Grant, Rt. 1, Box 363, Sneeds Ferry, N. C. 28960.

**Recovery of Foot-Pox Diseased Red-Winged Blackbird.**—S. Prentis Baldwin (*Auk*, **39**: 219) reported that nearly 10% of the Chipping Sparrows (*Spizella passerina*) which he trapped in 1921 at his Thomasville, Georgia station were infected with foot-pox. T. E. Musselman (*Auk*, **45**: 137) reports that in 1922 L. R. Talbot, banding at Baldwin's station, found that nearly 25% of Chipping Sparrows he banded had foot-pox. The following year, 1923, Musselman (*ibid.*) banded 519 Chipping Sparrows and had 44 returns. Of these 563 sparrows, 23% were suffering from foot-pox and 19% showed evidence of the disease in previous years but had healed entirely. John B. May (*Auk*, **41**: 456) banding at the same station in 1924 found the Chipping Sparrows very scarce and almost none with active foot-pox disease but they did have evidence of healed old cases. He was unable to collect an active sample.

C. Brooke Worth (*Auk*, **73**: 230-234) found foot-pox occurring naturally in the Blue Jay (*Cyanocitta cristata*), Chimney Swift (*Chaetura pelagica*) and Slate-colored Junco (*Junco hyemalis*). He conducted experiments with "Junco Virus" taken from a foot-pox lesion and found it infected some but not other birds introduced artificially. Herman, Locke and Clark (*Bird-Banding*, **33**: 191-198)