

## INTRASPECIFIC VARIATION IN THE HINDLIMB MUSCULATURE OF THE HOUSE SPARROW<sup>1</sup>

SUSAN BERMAN, MAURIZIO CIBISCHINO, PAUL DELLARIPA, AND LINDA MONTREN  
*Department of Biology, College of the Holy Cross, Worcester, MA 01610*

**Abstract.** We dissected the hindlimb musculature of 40 House Sparrows (*Passer domesticus*) in order to assess the degree of anatomical variation that one might expect within a bird population. We found four variations, which, if encountered in a single specimen, could lead to erroneous systematic conclusions. *M. iliofemoralis*, normally absent in passerines, was present in one specimen. In 10 of the 40 specimens *M. puboischiofemoralis* had an "extra" head. *M. flexor hallucis longus* typically arises by three heads in passerines. In 21 of our specimens only two heads were present. Finally, one specimen had an unusual relationship between the tendons of *Mm*, *fibularis longus* and *flexor perforatus digiti III*. All variations were present bilaterally. We hope that this study will promote an awareness that anatomical generalizations based on small sample sizes may be incorrect.

**Key words:** *House Sparrow; intraspecific variation; anomalies; hindlimb musculature; morphology.*

How confident can we be in the accuracy of anatomical descriptions that are based on the dissection of only a few specimens? Anatomical teaching labs abound with anomalies. Berger (1956) provides numerous examples of intraspecific variation in the morphology of humans as well as that of birds. Studies of appendicular musculature, a method used in elucidating phylogenetic relationships (Borecky 1977; Raikow 1977, 1978, 1985, 1987; Bentz 1979; Maurer and Raikow 1981; Swierczewski and Raikow 1981; McKittrick 1985a, 1985b, 1986) have also revealed deviations from what is accepted as typical for a particular species. This is unsettling, as time constraints and availability of specimens usually preclude the use of large sample sizes in studying myology, thus leading to the possibility that a species may be mischaracterized by an anomalous specimen.

To gain insight into how much anatomical variation might be expected within a bird population, we dissected the hindlimb muscles of 40 House Sparrows (*Passer domesticus*) collected from a farm in Princeton, Wisconsin. We found four variations from what has been described for this species. All were present bilaterally.

*M. caudo-ilio-femoralis.* This muscle consists

of two heads in birds. *Pars caudofemoralis* originates on the pygostyle and inserts on the caudolateral surface of the femur, proximal to the insertion of *M. pubo-ischio-femoralis*. *Pars iliofemoralis* arises on the ilium and inserts on the femur with *pars caudofemoralis*. Some groups retain both heads, this being regarded as the primitive condition. In other groups only one head is present. Although *pars iliofemoralis* is typically absent in passeriform birds (Fig. 1A), in one of our 40 specimens this muscle was present and clearly defined (Fig. 1B). As a primitive condition, this is very likely an example of atavism (Raikow 1975, Raikow et al. 1979).

*M. pubo-ischio-femoralis.* In passeriform birds this muscle typically consists of a cranial and a caudal head. Both arise from the ventrolateral margin of the ischium and insert on the caudal surface of the femur (Fig. 2A). In 10 of the 40 specimens there was a distinct third head (Fig. 2B). Its origin is about 3 mm cranial to that of *pars caudalis* and it inserts with *pars caudalis* on the caudal surface of the distal end of the femur. We have named this muscle *pubo-ischio-femoralis pars interna*. A third head of this muscle (called *pars accessoria*) has been described in only one other group, the Coliiformes (Berman and Raikow 1982), but it is quite different in position and appearance than the one described here, and hence probably arose independently.

As we regard this to be a derived, rather than

<sup>1</sup> Received 3 July 1989. Final acceptance 19 September 1989.

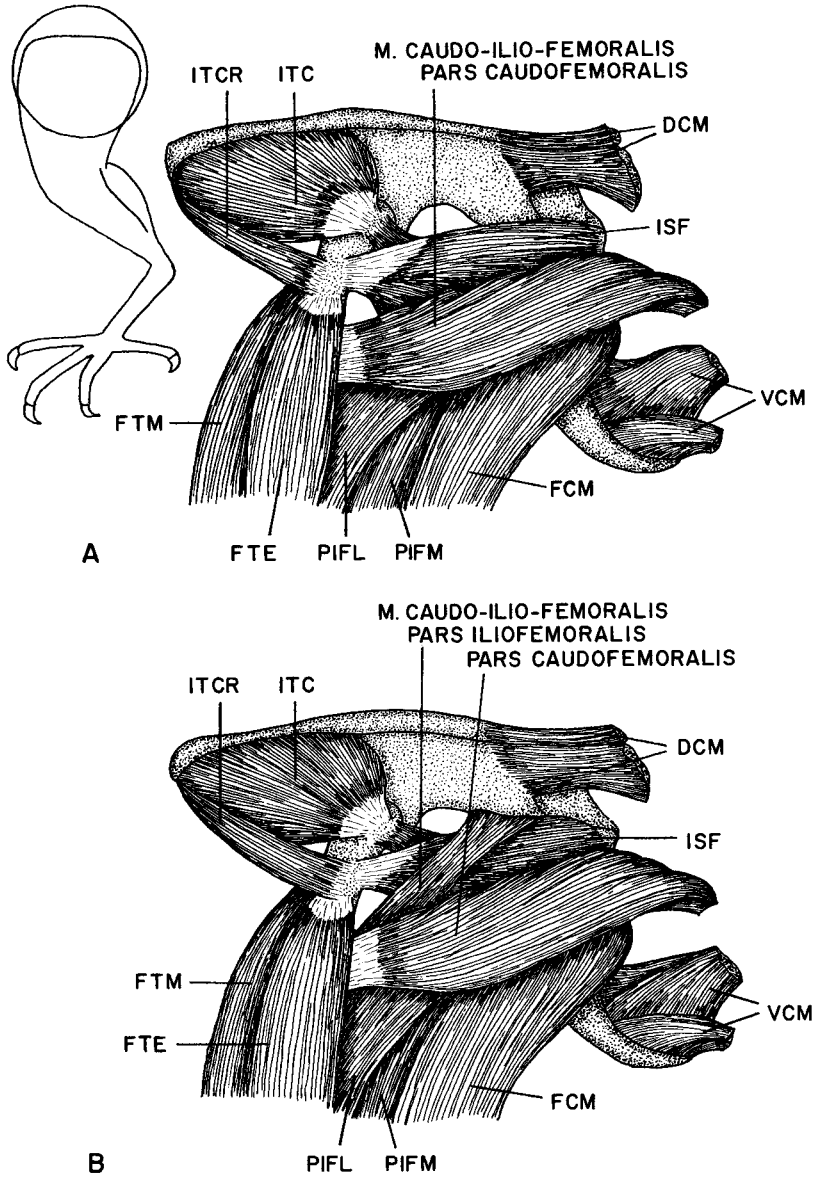


FIGURE 1. Left, lateral upper thigh of *Passer domesticus*. (A): Typical condition in passeriform birds, with only pars caudofemoralis of *M. caudo-ilio-femoralis* present. (B): Condition found in one out of 40 specimens, with both pars caudofemoralis and pars iliofemoralis of *M. caudo-ilio-femoralis* present. Abbreviations: DCM, dorsal caudal muscles; FCM, *M. flexor cruris medialis*; FTE, *M. femorotibialis externus*; FTM, *M. femorotibialis medius*; ISF, *M. ischiofemoralis*; ITC, *M. iliotrochantericus caudalis*; ITCR, *M. iliotrochantericus cranialis*; PIFL, *M. pubo-ischio-femoralis pars lateralis*; PIFM, *M. pubo-ischio-femoralis pars medialis*; VCM, ventral caudal muscles.

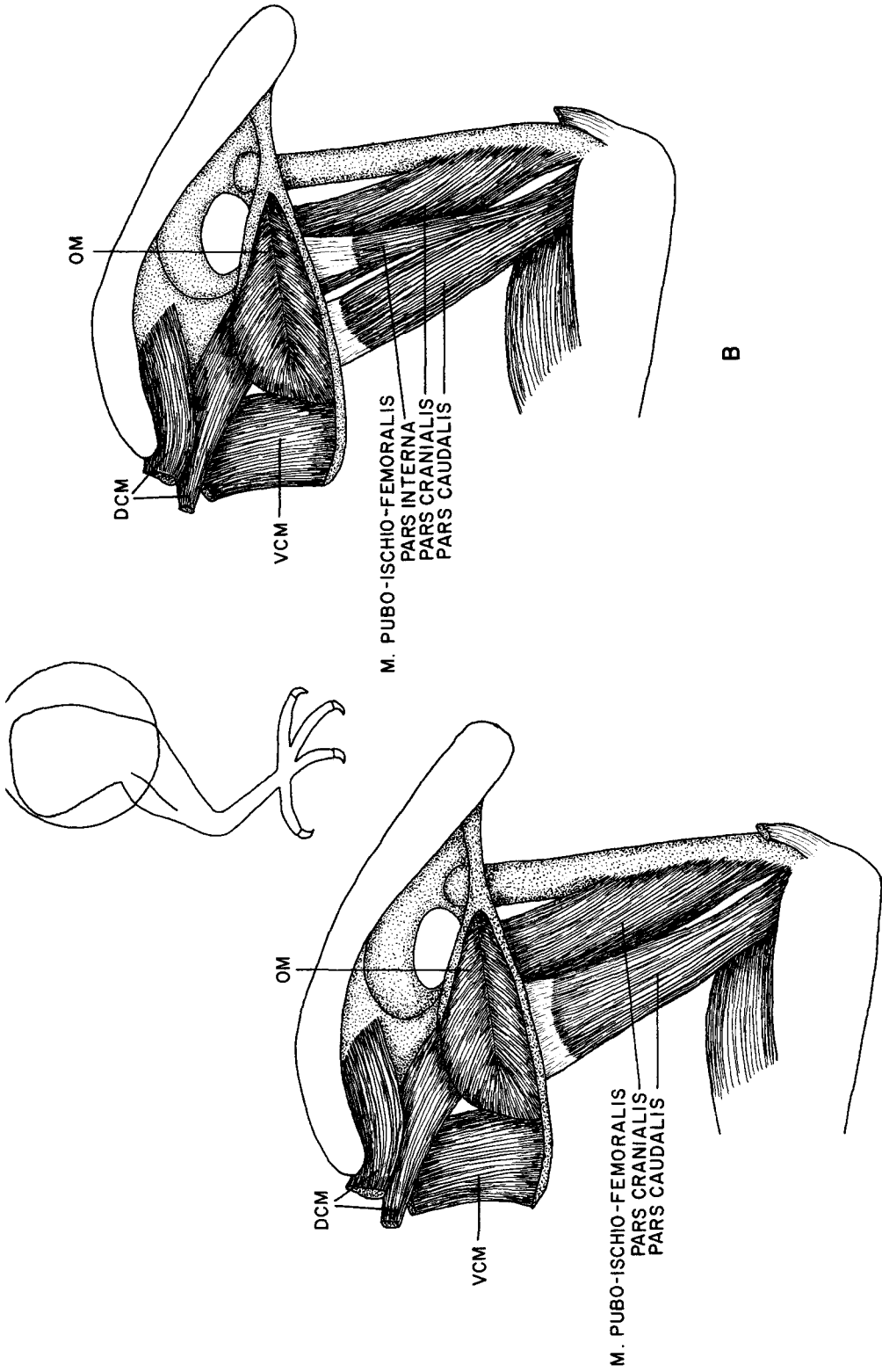


FIGURE 2. Left, medial thigh of *P. domesticus*. (A): Typical condition in passeriform birds, with only cranial and caudal heads of *M. pubo-ischio-femoralis* present. (B): Condition found in 10 of 40 specimens, with a third head, *M. pubo-ischio-femoralis* pars interna, present. Abbreviations: DCM, dorsal caudal muscles; OM, *M. obturatorius medialis*; VCM, ventral caudal muscles.

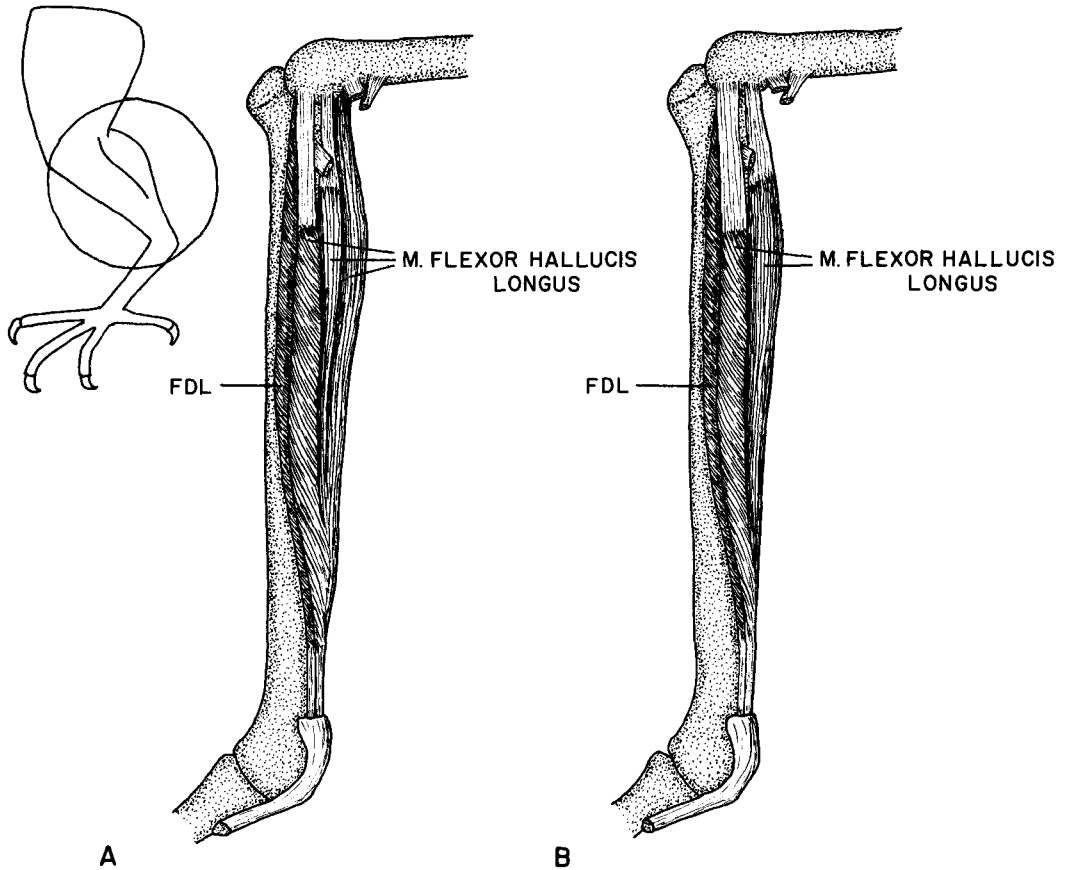


FIGURE 3. Left, lateral shank of *P. domesticus*. (A): Condition found in 19 of 40 specimens, with three heads of *M. flexor hallucis longus* present. (B): Condition found in 21 of 40 specimens, with only two heads of *M. flexor hallucis longus*. Abbreviation: FDL, *M. flexor digitorum longus*.

ancestral condition, its presence cannot be attributed to atavism. Given the high frequency of this variation, we suggest that its presence or absence be considered as a polymorphic trait.

*M. flexor hallucis longus*. The origin of this muscle varies among passerine birds. George and Berger (1966) state that it typically arises by two heads. More recent studies (Raikow 1976, 1978; Borecky 1977; Bentz 1979; Raikow et al. 1980) have found that it usually arises by three heads, lateral, intermediate, and medial. McKittrick (1985) found five variations in the origin of this muscle within the Tyrannidae, some of which are intraspecific. In 19 of our 40 specimens three heads are present. Lateral and intermediate heads arise from the lateral surface of the lateral femoral condyle, and are separated by the tendon of *M. iliofibularis*. The medial head arises from the

intercondylar region (Fig. 3A). In 21 of our 40 specimens the position medial to the iliofibularis tendon is not divided into intermediate and medial heads and there are no fibers arising from the intercondylar region (Fig. 3B). The two heads arise in a conventional manner from the lateral femoral condyle and are separated by the tendon of *M. iliofibularis*. In these specimens the undivided head medial to the iliofibularis tendon is enlarged, causing the entire muscle to appear about equal in size to those with three heads of origin.

In all of the specimens the two or three heads fuse about two-thirds of the way down the shank to form a common belly that gives rise to the tendon of insertion.

The high frequency of this variant (nearly 50% of our sample), suggests that the presence of two

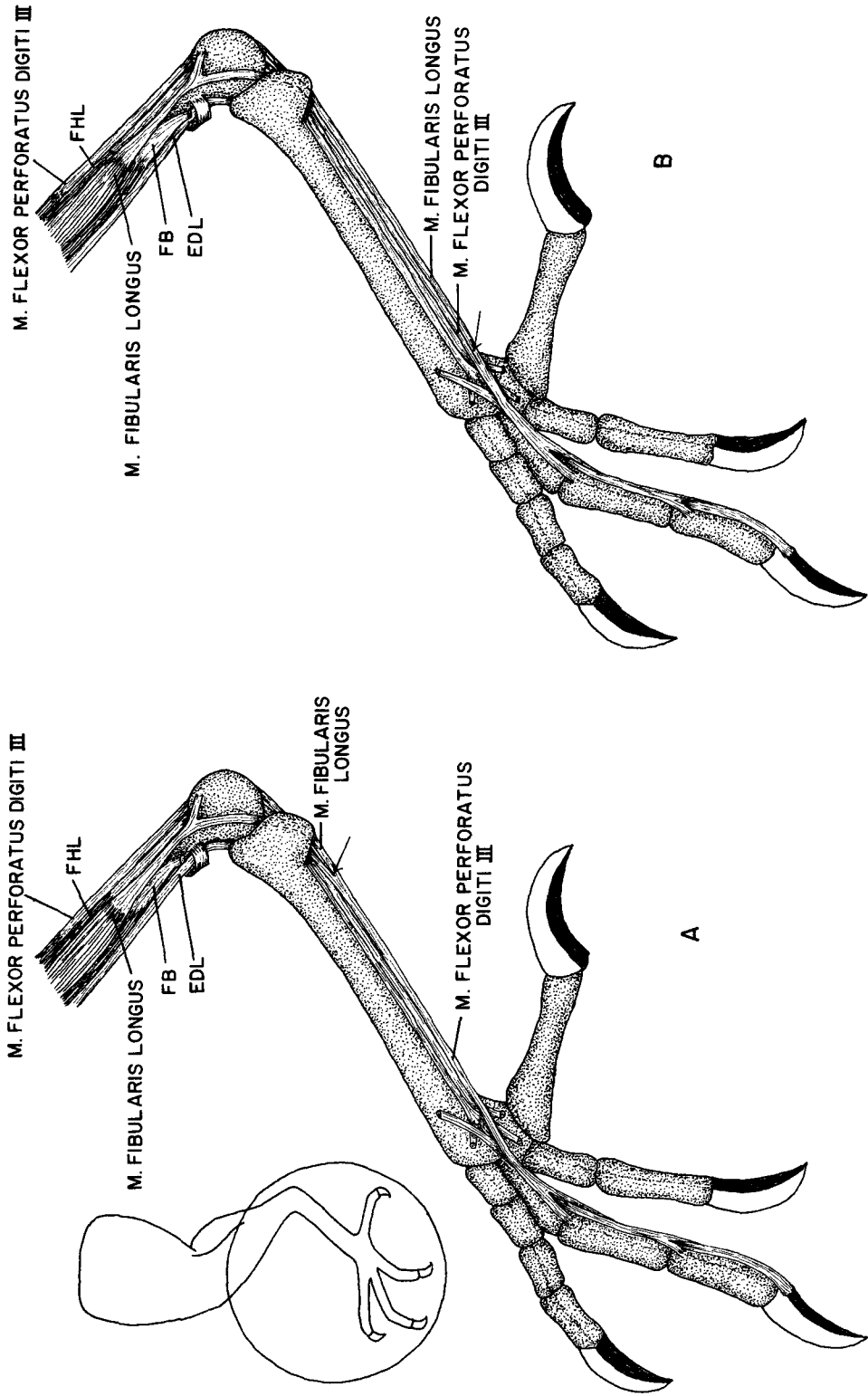


FIGURE 4. Left, lateral distal shank and pes of *P. domesticus*. (A): Typical condition, in which one branch of the fibularis longus tendon inserts on the tendon of *M. flexor perforatus digiti III* just distal to the hypotarsus. The arrow indicates the point of insertion of the fibularis longus tendon on the flexor perforatus digiti III tendon. (B): Condition in one of 40 specimens, in which the fibularis longus tendon extends all the way to the third digit. The arrow indicates the insertion of the flexor perforatus digiti III tendon on the fibularis longus tendon. Abbreviations: EDL, *M. extensor digitorum longus*; FB, *M. fibularis brevis*; FHL, *M. flexor hallucis longus*.

or three heads of *M. flexor hallucis longus* is a polymorphic trait in this population.

*M. fibularis longus*. The tendon of this muscle typically crosses the intertarsal joint and inserts on the tendon of *M. flexor perforatus digiti III* just distal to the hypotarsus (Fig. 4A). In one of our specimens the *M. fibularis longus* tendon continued distally to insert on the third digit. The tendon of *M. flexor perforatus digiti III* inserted on that of *M. fibularis longus* just proximal to the metatarsal-phalangeal joint (Fig. 4B).

We see no obvious functional significance to this variation. In either condition, both muscles would contribute to flexion of the third digit. As this condition has not been described in any other bird, it is very likely a random variation in this population.

*Conclusions*. The presence of two of these four variations in a relatively large proportion of the population should be of particular interest to morphologists who base systematic conclusions on small sample sizes. Whereas, for practical reasons, we doubt that these results will promote the use of large sample sizes in anatomical studies, they should at least foster an awareness that such variation may exist, and will contribute to our understanding of what types of variations occur and in what frequencies.

An obvious direction for future studies of intraspecific variation would be dissections of (1) House Sparrows in populations from other geographic areas, and (2) other species for which large numbers of specimens are easily obtainable.

#### ACKNOWLEDGMENT

We are grateful to R. J. Raikow for providing useful criticism of this manuscript.

#### LITERATURE CITED

- BENTZ, G. D. 1979. The appendicular myology and phylogenetic relationships of the Ploceidae and Estrildidae (Aves: Passeriformes). *Bull. Carnegie Mus. Nat. Hist.* 15:1-25.
- BERGER, A. J. 1956. Anatomical variation and avian anatomy. *Condor* 58:433-441.
- BERMAN, S. L., AND R. J. RAIKOW. 1982. The hindlimb musculature of the Coliiformes. *Auk* 99:41-57.
- BORECKY, S. R. 1977. The appendicular myology and phylogenetic relationships of the avian "corvid assemblage." Ph.D. diss. Univ. of Pittsburgh, Pittsburgh, PA.
- GEORGE, J. C., AND A. J. BERGER. 1966. *Avian myology*. Academic Press, New York.
- MAURER, D. R., AND R. J. RAIKOW. 1981. Appendicular myology, phylogeny, and classification of the Coraciiformes (including Trogoniformes). *Ann. Carnegie Mus.* 50:417-434.
- McKITRICK, M. C. 1985a. Pelvic myology of the kingbirds and their allies (Aves: Tyrannidae). *Ann. Carnegie Mus.* 54:275-317.
- McKITRICK, M. C. 1985b. Myology of the pectoral appendage in kingbirds (*Tyrannus*) and their allies. *Condor* 87:402-417.
- McKITRICK, M. C. 1986. Individual variation in the flexor cruris lateralis muscle of the Tyrannidae (Aves: Passeriformes) and its possible significance. *J. Zool. (Lond.) (A)* 209:251-270.
- RAIKOW, R. J. 1975. The evolutionary reappearance of ancestral muscles as developmental anomalies in two species of birds. *Condor* 77:514-517.
- RAIKOW, R. J. 1976. Pelvic appendage myology of the Hawaiian honeycreepers (Drepanididae). *Auk* 93:774-792.
- RAIKOW, R. J. 1977. The origin and evolution of the Hawaiian honeycreepers (Drepanididae). *Living Bird* 15:95-117.
- RAIKOW, R. J. 1978. Appendicular myology and relationships of the New World nine-primaried oscines (Aves: Passeriformes). *Bull. Carnegie Mus. Nat. Hist.* 7:1-43.
- RAIKOW, R. J. 1985. Systematic and functional aspects of the locomotor system in the scrub-birds, *Atrichornis*, and lyrebirds, *Menura* (Passeriformes: Atrichornithidae and Menuridae). *Rec. Austral. Mus.* 37:211-228.
- RAIKOW, R. J. 1987. Hindlimb myology and evolution of the Old World subsocial passerine birds (Acanthisittidae, Pittidae, Philepittidae, Eurylaimidae). *Ornithol. Monogr. No. 41*. American Ornithologists' Union, Washington, DC.
- RAIKOW, R. J., S. R. BORECKY, AND S. L. BERMAN. 1979. The evolutionary reestablishment of a lost ancestral muscle in the bowerbird assemblage. *Condor* 81:203-206.
- RAIKOW, R. J., P. J. POLUMBO, AND S. R. BORECKY. 1980. Appendicular myology and relationships of the shrikes (Aves: Passeriformes: Laniidae). *Ann. Carnegie Mus.* 49:131-152.
- SWIERCZEWSKI, E. V., AND R. J. RAIKOW. 1981. Hindlimb morphology, phylogeny, and classification of the Piciformes. *Auk* 98:466-480.