

# CINERADIOGRAPHIC STUDIES OF GASTRIC MOTILITY IN THE GREAT HORNED OWL (*BUBO VIRGINIANUS*)

D. D. RHOADES

AND

G. E. DUKE

Gastric motility in the Great Horned Owl (*Bubo virginianus*) has been the subject of few previous studies. A gastroduodenal contraction sequence beginning with the glandular stomach (proventriculus), then the muscular stomach (gizzard), and lastly the duodenum was observed radiographically by Reed and Reed (1928) and Kostuch and Duke (1975). Contractions arise near the isthmus in the muscular stomach and move around the greater curvature to the pyloric area. Kostuch and Duke (1975) also studied intragastric pressures telemetrically and described three phases in the frequency and amplitude of gastric motility during the digestion of a meal. The apparent purpose of each phase was postulated but not determined experimentally. That these phases were initiated upon eating, or even upon seeing food, was demonstrated by Duke et al. (1976a) using strain gauge transducers implanted on the muscular stomach to monitor gastric motility.

Gastric contractions which formed the gastric contents into a pellet were described from serial radiographs by Grimm and Whitehouse (1963) and via fluoroscopy by Reed and Reed (1928), but pellet egestion was not observed in these studies. Intense electrical and contractile events occurring in the esophagus, muscular stomach, and duodenum preceding and during pellet egestion have been detected by implanted electrodes and strain gauge transducers and recorded (Duke et al. 1976b). They were correlated with simultaneous radiographic observations of gastric motility.

Other gastrointestinal motility studies of raptors were performed by Dedic (1930) on European Goshawks (*Accipiter gentilis*) and Mangold (1911) on a Common Buzzard (*Buteo buteo*).

As much remains to be learned about gastric digestion in owls, we undertook to (1) further characterize the phases of digestive motility in the muscular stomach by another method, *viz.* cineradiography, (2) help determine the function of each phase by removing and examining gastric contents during these phases, and (3) observe pellet egestion and

relate the gastric contraction pattern during the egestion process to patterns observed during other phases in digestive motility.

## METHODS

Thirteen adult Great Horned Owls were used, eight of which had been raised in captivity and were in excellent health. The other five owls were hopeless cripples received from the raptor rehabilitation program associated with our laboratory. Although these owls had permanent disabilities, they were healthy and ate well, and they were regarded as normal with respect to digestive function. All birds were weighed frequently during the study, and no significant weight variations were noted.

The owls were housed in an environmentally-controlled room in which the photoperiod was regulated to simulate natural daylength, and the temperature and humidity were maintained at 25–27°C and 45–50%, respectively.

Freshly frozen laboratory mice (*Mus musculus*), the diet for the owls throughout the study, were normally provided *ad libitum*, but for 24 h prior to any trial the owls were not fed to insure that no food remained in the upper digestive tract. During or just before the trials, the owls were fed two mice weighing about 30 g each. As the lengths of the phases in post-prandial gastric motility vary with meal size (Kostuch and Duke 1975), a standard meal size was used to try to standardize phase lengths in this study.

A cineradiographic unit (Emperor 90/15 table, 6 inch image intensifier, 875 line split T.V., 35 mm cine, jupiter 90 MA control and transformer, Prof-ray, Des Plaines, IL) which allowed both closed-circuit television monitoring and recording on 35 mm film (double negative film, type 5222, DXN 718, Eastman Kodak, Oak Brook, IL) was used. Radiographic observations were made from a right lateral view with the owl standing on a perch. However, a left lateral view appeared on the TV monitor (Fig. 1). Care was taken to avoid exposing any owl to excessive x-radiation. For convenience in describing gastric motility, the face of a clock was mentally superimposed on the radiographic image of the muscular stomach (Fig. 1); areas of the muscular stomach were identified by referring to their clock positions with 1200 being at the isthmus, 0100 being immediately caudodorsal to the isthmus, etc.

To observe swallowing and the first half of gastric digestion, owls were fed after being placed on the cine unit. To observe the last half of gastric digestion and pellet egestion, owls were fed 8–10 h before being placed on the cine unit. In a few experiments, owls were fed while on the unit, and short observations were made throughout the entire gastric digestion process. Each of the eight intact owls was observed for 30–34 h; the cripples were observed for

1.5–4 h each. Processes observed radiographically were further analysed by viewing films.

Approximately 4 ml of  $\text{BaSO}_4$  was administered orally as an aqueous suspension immediately after a meal of two mice was swallowed and throughout the trials as required. This radiopaque substance outlined the lumen of the gastrointestinal tract, allowing observation of contractions and fluxes of ingesta and also coated the pellet as it was being formed in the stomach. Additionally, 2–3 ml of  $\text{BaSO}_4$  suspension plus two pieces of plastic-coated copper wire formed into distinguishable shapes (e.g., X, O, V, 8) were put into the abdominal cavities of each mouse. This aided in radiographic determination of the position of ingested mice, and the wires aided observations of the formation and movement of pellets.

The permanently crippled owls were sacrificed during specific phases of digestion (sodium pentobarbital, 12 ml at 65 mg/ml, I.V.) in order to determine the state of ingesta.

## RESULTS

### SWALLOWING

We defined swallowing as passage of a mouse from the mouth of an owl until it was entirely within the muscular stomach. Mice were swallowed whole, head first. Extension of the neck and quick head jerks assisted in moving a mouse into the esophagus where peristalsis moved it into the glandular stomach. The mouse was also moved into the muscular stomach by peristalsis of the glandular stomach as well as by contractions of the muscular stomach. A second mouse was held in the glandular stomach for 2–3 min while contractions of the muscular stomach moved the first mouse from under the isthmus to the pyloric side of the muscular stomach thus permitting passage of the second mouse into the muscular stomach. Average swallowing times for the first and second mice of a two-mouse meal were 2.8 and 4.2 min, respectively. Both radiographic observation of the muscular stomach and palpation of it through the abdominal wall indicated that it was about three times larger and much rounder immediately postprandially than preprandially.

After both mice were swallowed and 4 ml of  $\text{BaSO}_4$  had been administered, the isthmus usually appeared constricted. Whether the isthmus was constricted or not, it was never a barrier to fluids passing aborally, but oral movement of ingesta from the muscular stomach to the glandular stomach almost never was seen.

### PHASE OF GASTRIC DIGESTION

We distinguished seven phases in the gastric digestion of a meal consisting of two mice: I) Filling; II) Early chemical digestion; III) Late chemical digestion; IV) Fluid evacua-


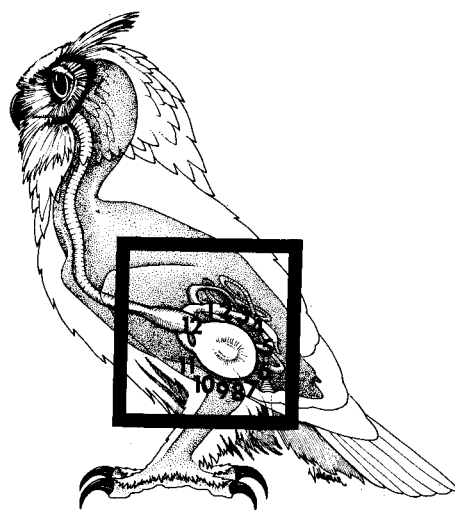


FIGURE 1. Orientation of the upper gastrointestinal tract of a Great Horned Owl from a left lateral view (upper) and enlargement (lower) of the enclosed area showing the muscular stomach with clock-face numbers used in describing the positions of contractions during radiographic observations.

tion; V) Early pellet compaction; VI) Late pellet compaction; VII) Final pellet formation and egestion. Some of the phases were similar; however, each phase had characteristics which distinguished it from all other phases with some overlap during brief (5–10 min) transition periods between phases. Gastric digestion appeared to be a dynamic process with no slack periods throughout the digestion cycle.

*Phase I: Filling.* This phase, lasting 50–60 min, began upon arrival of the first of two mice in the glandular stomach. The contractions of the muscular stomach, characterized

TABLE 1. Characteristics of muscular stomach activity during each phase of gastric digestion of a meal of two mice by Great Horned Owls.

Phase	$\bar{x}$ Length	Contraction		Function of phase	Cond. stomach contents	Size, shape of stomach	BaSO <sub>4</sub> clearance (ml/h)*	
		Area of stomach	Type					Frequency (cycles/min)
I	50-60 min	0100- 1100	Very vigorous; deep indenting	3	Filling stomach	Damp; no digest.	Round; greatly enlarged	2
II	4.5-5 h	0100- 1100	Indented; moderately vigorous	2	Initial chem. digest.	Most flesh digested	Same as Phase I	3
III	3-3.5 h	0100- 1100	Flat, large (3 clock positions at once)	1-1.5	Final chem. digest.	Only undigestible material left	Size decreasing	3-4
IV	30-45 min	0100- 1100	Very vigorous; paired; indented	2-3	Fluid evacuation	Damp undigest. material in loose mat	Size decreasing; elongated	12-15
V		0300- 0900	Flat; moderately vigorous	1-1.5	Initial pellet compaction	Drier undigest. material; loosely packed	Size decreasing; elongated	12-15
Combined								
VI	5-6 h	0100- 1100	Paired, indented; unpaired, flat-vigorous	1.5-2	Pellet formation	Tightly packed, assuming pellet shape	Size decreasing; increased elongation	1-2
VII	12-20 min	0700-1100 and 0400-0700	2 types: 4-7 o'clock very indented, 7-11 o'clock large & flat; both vigorous	3-4	Pellet expulsion	In pellet form	Return to small, round shape	

\* This represents the rate at which additional injections of the BaSO<sub>4</sub> suspension had to be made in order to maintain a useful outline of the stomach.

by a very deep indentation of the lumen, began at the 0100 position and swept very rapidly around the greater curvature in a clockwise manner to the 1100 position where they faded (Fig. 2). These contractions were so frequent that there was little delay between the end of one and the beginning of the next. Often, early in the phase, a new sequence would begin before the preceding one was completed. The force of contractions, as judged by the depth of the indentation of the muscular stomach lumen, appeared to be greater during this phase than in any other. The frequency of contraction cycles also appeared to be the highest during this phase except for the pellet egestion phase (Table 1).

Usually, in all phases, when the contraction moved across the 1000 position (pylorus), a stream of BaSO<sub>4</sub> left the muscular stomach and entered the proximal duodenum. As the body cavities of the mice were still intact during Phase I (Table 1), this BaSO<sub>4</sub> was that which was administered orally to the owl.

*Phase II: Early chemical digestion.* Phase II lasted 4.5-5 h. The contractions of Phase II seemed less forceful than those of Phase I, appearing as a flattening of the muscular stomach lumen rather than as an indentation.

The frequency of contraction cycles also declined dramatically and each cycle took longer to move around the greater curvature of the stomach.

During Phase II, the plastic-coated copper wires were observed to move in a continuous clockwise circuit within the muscular stomach, and 15-30 min were required for one wire to make a complete circuit. While refluxing of ingesta in the intestines was seen, no refluxing was observed between the duodenum and the muscular stomach or between the muscular and the glandular stomachs.

A crippled owl that had been fed one black (B) and one white (W) mouse was sacrificed 30 min after the beginning of Phase II, or about 1.5 h after being fed. Examination of the gastric contents revealed that both mice were still partially intact and could be removed individually from the muscular stomach. The mice were wet, and their fur was coated in some areas with BaSO<sub>4</sub>. The mucosal lining of the muscular stomach of the owl was very damp; however, little gastric juice was present. During feeding, the owl had crushed the skull and punctured the abdomen of mouse B. Gross examination of the ingesta showed that (1) the skin and

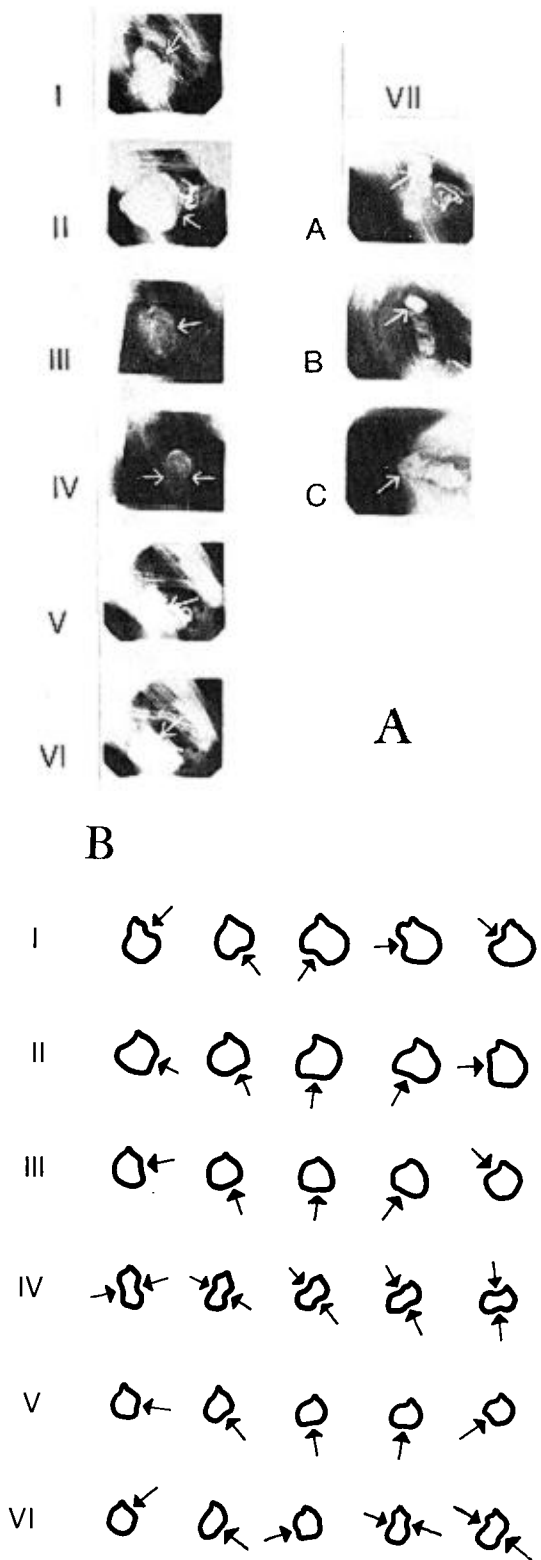


FIGURE 2. A. I-VI are sample left lateral radiographs of a Great Horned Owl showing the relative size and configuration of the lumen of the muscular stomach during each of the first six phases in the gastric digestion of a meal of two mice. Radiographs VII A-C, taken during pellet formation and egestion, show the upper one-third of a pellet in a glandular

muscle of the abdomens of both mice were absent. (2) The stomach and intestines of mouse B were apparently completely digested while small amounts of intestinal tissue remained in mouse W. (3) The kidneys and livers were undigested in both mice. (4) The head of mouse B was almost completely digested; some skull fragments were attached to the lower jaw by fur-covered skin. Mouse W showed no sign of digestion in the head region. (5) The feet and tails of both mice showed no signs of digestion. (6) Tissues in the thoracic cavity of mouse B appeared to be somewhat digested while the same area in the mouse W showed no digestion. (7) There was no noticeable amount of ingesta or BaSO<sub>4</sub> in the duodenum of the owl or any other part of its small intestine. A second adult owl was sacrificed 3.5 h after the beginning of Phase II because at this time the paired copper wires which had been placed in the abdominal cavity of each mouse were separated, indicating that the mice were no longer intact. Both the glandular and the muscular stomachs of the owl were opened, and gross examination disclosed that (1) the ingesta formed a loosely packed, nearly homogeneous mass with a pasty texture. However, some of the more heavily muscled parts of the mice (e.g., hind legs) were still distinguishable. (2) Many small pieces of skin with attached fur as well as unattached fur were mixed throughout the ingesta. (3) Some articulating bones such as those of the tail and feet were still held together by ligaments and cartilage. However, the skin and muscles associated with these bones were gone. (4) One of the plastic-coated wires, but no ingesta, was found in the glandular stomach. (5) Ingesta associated with BaSO<sub>4</sub> were found throughout the entire intestinal tract of the owl. Their texture ranged from pasty in the duodenum to liquid in the jejunum and ileum.

*Phase III: Late chemical digestion.* Phase III lasted 3-3.5 h, and late in this phase the muscular stomach had decreased to about two-thirds of its size during Phase II. Phase III was very similar to Phase II (Fig. 2B). However, the frequency of contraction cycles

← stomach, the upper one-half of a pellet in an esophagus, and an entire pellet in the esophagus moving orad through the thoracic inlet, respectively. Arrows indicate positions of gastric contractions (I-VI) or pellets (A-C). B. Outline drawings taken from radiographs showing relative changes in the configuration of the muscular stomach lumen during a typical contraction cycle for six of the phases in gastric digestion. Arrows indicate the positions of contractions.

declined further, and the cycles took longer to go around the greater curvature than in the previous phase (Table 1). The contractions were flat like those in Phase II, but contractions seemed more massive, generally flattening the whole right side of the muscular stomach, then the bottom, and then the left side. More BaSO<sub>4</sub> was observed leaving the muscular stomach than in the previous phases.

Examination of the gastrointestinal contents of an owl sacrificed 7.5 h after feeding (late in Phase III) indicated that (1) no ingesta were found in the glandular stomach. (2) Very few ingesta were found in the intestinal tract. (3) The muscular stomach contained principally thoroughly mixed fur and bone which filled the entire lumen and showed no signs of compaction. Only trace amounts of flesh were found.

*Phase IV: Fluid evacuation.* This phase was very short, lasting only 30–45 min. It was very different from the previous phase in that there was a transition into “paired” contractions of the muscular stomach (Fig. 2B). A contraction sequence was considered to begin when a new contraction began at the 0100 or 0200 position while the muscular stomach was still contracted at the 0700 or 0800 position from the previous cycle. Then, these two opposing contractions moved around the stomach in a coordinated pattern, always diametrically opposite each other. The sequence was considered to be over when the aborad contraction of a pair reached the 1100 position and waned leaving the more orad contraction at the 0600 or 0700 position to become the aborad contraction in a new pair. The contractions had the appearance of more shallow indentations than those of Phase I. Cycles became more frequent during this phase, and fluid was very rapidly evacuated from the stomach so that about 3 ml of BaSO<sub>4</sub> suspension had to be administered every 7–12 min in order to keep the stomach lumen outlined (Table 1). Sometimes the suspension was delayed in the glandular stomach for a few minutes and slowly passed into the muscular stomach. Fluid administered during the transition between Phases IV and V caused Phase IV contractions to begin again, apparently indicating that Phase IV is associated primarily with fluid evacuation and not with pellet formation. The muscular stomach was reduced to about half its Phase I size.

Examination of the digestive tract of an owl sacrificed 15 min after the paired contractions began disclosed (1) no ingesta in the glandular stomach. (2) The muscular stomach contents appeared as a very damp, homogeneous,

shapeless mass of hair and bone that filled the entire lumen. (3) Only fluid was present in the intestine.

*Phase V: Early pellet compaction.* Phases V and VI often were reversed in their order of occurrence, and in some experiments several transitions back and forth between the two phases occurred. The two phases combined lasted 5–6 h, but their exact durations were variable.

In Phase V the contractions were exactly as in Phase III in that they were generally flat, somewhat massive and slow-moving around the greater curvature. Often the contraction of the 0500–0700 area of the muscular stomach persisted for 5–10 s before continuing. The little movement of the wire markers that occurred appeared to be random rather than the uniform clockwise circulation described previously.

*Phase VI: Late pellet compaction.* The contractions of Phase VI were similar to those of Phase V. However, the movement of the wave of contraction along the 0500–0700 area of the stomach was not delayed. Instead, the contraction was delayed on the left side of the stomach while a new contraction arose on the right side. These contractions moved somewhat like the paired contractions of Phase IV in a coordinated fashion around the greater curvature. However, unlike Phase IV, both contractions of the pair faded simultaneously as the first contraction reached the 1100 position. Then the cycle began again with a new contraction on the right side of the stomach. Often during this phase, the lumen of the stomach appeared elongated (similar to the shape of the pellet; Fig. 2B) as the contractions occurred simultaneously on the right and left sides of the stomach.

An owl was sacrificed during Phase VI at a time estimated to be 45–90 min prior to the probable egestion of the pellet. An examination of the gastrointestinal tract revealed that (1) there were no ingesta in the glandular stomach or small intestine. (2) Only hair, bones, and the copper wire markers were found in the muscular stomach. This mass was damp but drier than in earlier stages of digestion. (3) Although the hair and bones were tightly compacted, they were not yet completely in the typical elongated pellet form. (4) The main body of the “forming pellet” was lying against the pyloric side of the muscular stomach. In fact, a portion of the pellet was protruding into the pylorus.

*Phase VII: Final pellet formation and egestion.* Usually the muscular stomach became almost quiescent late in Phase VI, 30–60 min

prior to the transition to Phase VII. Within 2–3 min after Phase VII started, the pellet began moving very slowly out of the muscular stomach and into the glandular stomach. The movement from the muscular stomach and out of the mouth appeared to be a continuous process which required 8–15 min.

During Phase VII two separate contractions occurred, the first in the 0400–0800 area of the stomach and the second on the left side of the stomach. The first contraction was like the deep indentation seen in Phase I except that it arose at the 0400 position and faded at the 0800 position during Phase VII. This contraction tended to push the pellet material up against the isthmus. The left side of the stomach contracted as described in Phase III except that it now included the 1100–1200 portion of the stomach so that the area under the pylorus, which had previously formed a pocket, was collapsed downward toward the center of the muscular stomach. Any material therein was pushed directly under the isthmus and compacted against the right side of the muscular stomach. These two contractions occurred very rapidly and continued for 1–3 min after the pellet was completely out of the muscular stomach and into the glandular stomach. Antiperistalsis in the glandular stomach (which we could not detect) may have assisted in moving the pellet into the esophagus. Once the pellet was entirely out of the stomach, antiperistalsis moved the pellet up the esophagus (esophageal antiperistalsis was observed). When the pellet was partially through the thoracic inlet of the esophagus, the owl simply lowered its head and the pellet dropped out. The pellet was easily seen as it moved (Fig. 2A) due to the contained BaSO<sub>4</sub>, wire markers, and mouse bones.

#### ANTIPERISTALSIS IN THE RECTUM

Antiperistalsis was observed in the rectum. It ceased just prior to defecation and resumed shortly afterward, as has been reported previously for turkeys (Dziuk 1971).

#### DISCUSSION

The basic gastric contraction sequence for Great Horned Owls as described herein and previously (Reed and Reed 1928, Kostuch and Duke 1975) is considerably different from the more complex contraction sequence in the muscular stomach of turkeys (Dziuk and Duke 1972). Reed and Reed (1928) believed that gastric contractions in Great Horned Owls were "very gentle," and they observed no extensive gastric motility. Likewise, Man-

gold (1911), using balloon pressure methods, recorded very low amplitude gastric motility in the Common Buzzard. Our radiographic observation of apparently very vigorous gastric contractions disagrees with the observations of Reed and Reed (1928). The mean intragastric pressures of very high amplitude recorded by Kostuch and Duke (1975) disagree with the findings of Mangold (1911) but corroborate the observations presented here. Perhaps the type of equipment used, the methods by which observations were made, and/or the phase of gastric digestion during which recordings or observations were made may account for these differences.

The three phases of gastric digestion described by Kostuch and Duke (1975)—I. Mechanical digestion, II. Chemical digestion, and III. Pellet formation and egestion—correspond, respectively, to Phases I and II, III and IV, and V, VI and VII described here.

The enlargement of the muscular stomach just after eating and the gradual reduction in size during the digestive sequence which we observed agree with the findings of Grimm and Whitehouse (1963) and Reed and Reed (1928).

Examination of the nature and volume of the contents of the gastrointestinal tract in the sacrificed owls assisted us in defining the function of each of the phases in gastric digestion. Phase I contractions moved mice into the pyloric side of the muscular stomach, but no noticeable digestion took place. Most of the digestion of the mice was accomplished during Phase II, very few identifiable parts remaining by the end of this phase. In Phase III the remaining flesh and cartilage were digested leaving only the undigestible portions of the meal in the muscular stomach. During Phases II and III, the more fluid portions of the ingesta were moved out of the muscular stomach. In Phase IV, paired contractions squeezed the fluids out of the mass of undigestible material in the muscular stomach. The contractions of Phase V and VI were erratic in their order of appearance but powerful (Kostuch and Duke 1975) and formed the pellet in the pyloric area of the muscular stomach. Grimm and Whitehouse (1963) also noted that the pellet was formed in the pyloric area. During Phase VII, two separate contractions previously reported by Duke et al. (1976b) moved the pellet out of the muscular stomach.

In conclusion, the muscular stomach of Great Horned Owls appears to be the site of initial proteolysis; chemical separation of soft tissues from hair and bone is completed

there. The contractile activity of the muscular stomach appears more vigorous than earlier reports indicated, and because phases in motility are associated with stages in the chemical digestion process, motility must significantly aid chemical digestion. Gastric motility is also essential for evacuating fluid from the muscular stomach after chemical digestion is complete, and for forming and egesting the pellet.

#### SUMMARY

Gastric motility during digestion of a meal of two mice and egestion of a pellet of undigestible materials from that meal were observed and filmed via cineradiography in 13 mature Great Horned Owls. Seven phases of gastric motility were observed: I) filling, II) early chemical digestion, III) late chemical digestion, IV) fluid evacuation, V) early pellet compaction, VI) late pellet compaction, VII) final pellet formation and egestion. Generally, these phases appeared in order. However, phases V and VI were quite variable in their order of appearance and duration.

#### LITERATURE CITED

DEDIC, S. 1930. Über Physiologische Formierung und Motilität der Verdauungsorgane beim Ha-

- bichten (*Astur palumbarius*). Fortschr. Geb. Roentgenstr. Nuklearmed. 43:367-371.
- DUKE, G. E., O. A. EVANSON, AND P. T. REDIG. 1976a. A cephalic influence on gastric motility upon seeing food in Domestic Turkeys (*Meleagris gallopavo*), Great-horned Owls (*Bubo virginianus*), and Red-tailed Hawks (*Buteo jamaicensis*). Poultry Sci. 55:2155-2165.
- DUKE, G. E., O. A. EVANSON, P. T. REDIG, AND D. D. RHOADES. 1976b. The mechanism of pellet egestion in Great-horned Owls (*Bubo virginianus*). Am. J. Physiol. 231:1824-1830.
- DZIUK, H. E. 1971. Reverse flows of gastrointestinal contents in turkeys. Fed. Proc. 30:610.
- DZIUK, H. E., AND G. E. DUKE. 1972. Cineradiographic studies of gastric motility in turkey. Am. J. Physiol. 22:159-166.
- GRIMM, R. J., AND W. M. WHITEHOUSE. 1963. Pellet formation in a Great Horned Owl. A roentgenographic study. Auk 80:301-306.
- KOSTUCH, T. E., AND G. E. DUKE. 1975. Gastric motility in Great Horned Owls (*Bubo virginianus*). Comp. Biochem. Physiol. 51(A):201-205.
- MANGOLD, E. 1911. Die Funktionellen Schwankungen der Motrischen Tätigkeit des Raubvogelmagens. Pfluegers Archiv Gesamte Physiol. Menschen Tiere 139:10-32.
- REED, C. I., AND B. P. REED. 1928. The mechanism of pellet formation in the Great Horned Owl (*Bubo virginianus*). Science 68:359-360.

Department of Veterinary Biology, University of Minnesota, St. Paul, MN 55108. Accepted for publication 30 November 1976.