

THE HINDLIMB MUSCULATURE OF THE WHITE-FRONTED AMAZON (*AMAZONA ALBIFRONS*, PSITTACIFORMES)

SUSAN L. BERMAN

Department of Biology, College of the Holy Cross, Worcester, Massachusetts 01610 USA

ABSTRACT.—The hindlimb musculature of six specimens of *Amazona albifrons* was dissected in order to (1) provide a detailed myological description, (2) provide a preliminary study and basis for a systematic analysis of the Psittaciformes, and (3) point out any myological peculiarities that might be associated with their unusually manipulative feet. Notable features include a peculiar positioning of *M. extensor brevis digiti IV*, a previously undescribed muscle to digit III, a peculiar arrangement of the short extensors of the hallux, and a branch of *M. extensor digitorum longus* to the hallux. These features are believed to be associated either with the zygodactyl digit configuration or the requirement of finer control over the individual digits. *Received 15 March 1983, accepted 8 July 1983.*

THE order Psittaciformes includes about 332 living species. If only external characters are considered, it is a relatively homogeneous group. Hence, there has never been any confusion as to whether or not a species belonged to the order. The Psittaciformes is so morphologically distinct from other avian orders, however, that even comprehensive recent works (Sibley and Alquist 1972, Cracraft 1981) have failed to elucidate its systematic position. Relationships within the order are also uncertain. The fundamental argument has been over the reality of what appears to be a very uniform group. Using a variety of anatomical characters, researchers have proposed as few as one and as many as 11 families (Garrod 1874, Salvadori 1891, Mivart 1895, Thomson 1899, Mudge 1902, Glenny 1957, Brereton 1963, Holyoak 1973, Homberger 1980).

Despite the invaluable anatomical information provided by these workers, the relationships within the Psittaciformes continue to be a matter of considerable confusion. There is a need for comprehensive studies using appropriate characters, along with a contemporary approach to analysis. Some of the more informative current avian phylogenies have been based on appendicular myology (Borecky 1977; Raikow 1977, 1978; Bentz 1979; Raikow et al. 1980; Sweirczewski and Raikow 1981; Maurer and Raikow 1981). A similar analysis of the Psittaciformes thus seems appropriate.

The present, primarily descriptive, account is the first in a planned series of studies of the hindlimb musculature of the Psittaciformes. A

comprehensive description of a parrot hindlimb has not been previously written. This study thus will not only be a first step toward a systematic analysis of the group but will provide a basis for future morphological comparisons with other avian orders.

MATERIALS AND METHODS

I dissected one hindlimb of each of six preserved specimens of *Amazona albifrons* under a stereomicroscope with a magnification of 6–25×. I used iodine stain (Bock and Shear 1972) to demonstrate small muscles clearly and to elucidate fiber architecture. Drawings were made with a camera lucida. Anatomical nomenclature is in accordance with the "Nomina Anatomica Avium" (Baumel et al. 1979).

DESCRIPTION OF HINDLIMB MUSCLES

M. iliotibialis cranialis (Figs. 1, 2: IC).—This strap-shaped muscle arises by fleshy fibers from the aponeurosis covering the dorsal surface of the most caudal vertebra, from the cranial 6 mm of the dorsal crest of the synsacrum, and from the cranial 3 mm of the aponeurosis that covers *M. ilirotrochantericus* caudalis. The muscle extends distally, defining the cranial border of the thigh. It narrows to about 4 mm to insert by fleshy fibers on the cranial cnemial crest of the tibiotarsus. In one specimen a few fibers insert on the aponeurosis of *M. femorotibialis internus* about 7 mm from the distal end of the femur.

M. iliotibialis lateralis (Figs. 1, 2: IL).—Only a preacetabular portion is present. The sheet-like muscle originates by an aponeurosis that extends along the caudal one-half of the dorsal iliac crest to the femoral trochanter. The aponeurosis completely covers *M. iliofemoralis externus* and the caudal one-half of *M.*

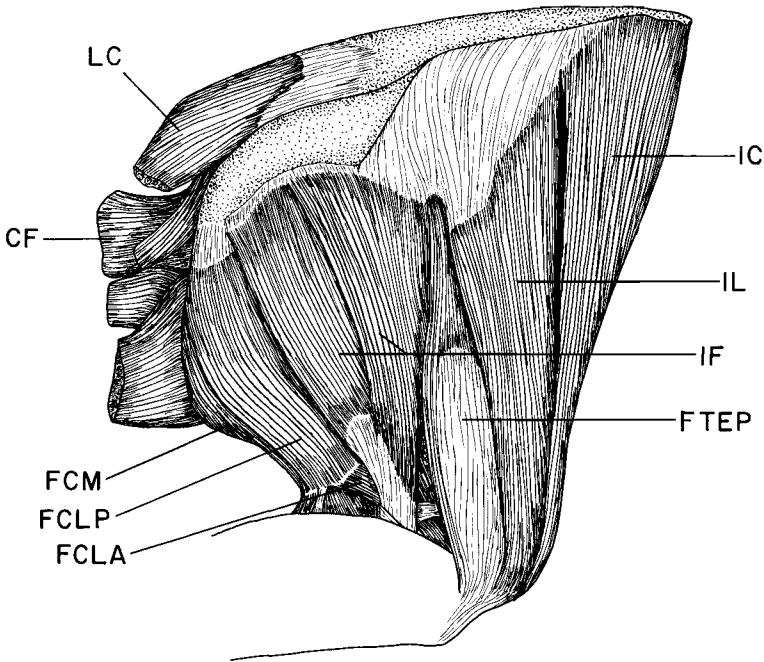


Fig. 1. Lateral view of the thigh of *Amazona albifrons* showing the superficial muscles. Note the absence of the postacetabular part of *M. iliotibialis lateralis* and the two heads of *M. iliofibularis*. Abbreviations for Figs. 1-4: AIF, ansa *M. iliofibularis*; CF, *M. caudofemoralis*; FCLA, *M. flexor cruris lateralis pars accessoria*; FCLP, *M. flexor cruris lateralis pars pelvica*; FCM, *M. flexor cruris medialis*; FTPE, *M. femorotibialis externus pars proximalis*; FTL, *M. femorotibialis internus*; FTM, *M. femorotibialis medius*; IC, *M. iliotibialis cranialis*; IF, *M. iliofibularis*; IFE, *M. iliofemoralis externus*; IFI, *M. iliofemoralis internus*; IL, *M. iliotibialis lateralis*; ISF, *M. ischiofemoralis*; ITC, *M. ilirotrochantericus caudalis*; ITCR, *M. ilirotrochantericus cranialis*; ITM, *M. ilirotrochantericus medius*; LC, *M. levator caudae*; OL, *M. obturatorius lateralis*; OM, *M. obturatorius medialis*; PIFL, *M. pubo-ischio-femoralis pars lateralis*; PIFM, *M. pubo-ischio-femoralis pars medialis*.

iliotrochantericus caudalis. The fleshy belly of *M. iliotibialis lateralis* is about 10 mm wide at its proximal end and lies superficial to *Mm. ilirotrochantericus caudalis* and *cranialis*. As it passes down the lateral surface of the thigh, its cranial border lies just deep to *M. iliotibialis cranialis* and its caudal border just superficial to *M. femorotibialis externus pars proximalis*. Distally, the muscle fuses with the aponeurosis covering the lateral surface of *M. femorotibialis externus*. This fusion begins caudally and extends cranially in the distalmost part of the muscle. The aponeurosis ultimately inserts on the patella. Just proximal to its insertion, the distalmost part of the belly of *M. iliotibialis lateralis* is about 2 mm wide and lies deep to the distal portion of *M. iliotibialis cranialis*.

M. ilirotrochantericus caudalis (Fig. 3: ITC).—This well-developed, fan-shaped muscle arises by fleshy fibers from the entire dorsal iliac fossa cranial to *M. iliofemoralis externus*. Its caudal border lies just deep to this muscle. *M. ilirotrochantericus caudalis* extends

caudolaterally, its fibers converging on a broad tendon to insert at the center of the femoral trochanter. The tendon narrows to about 2 mm at the point of its insertion. The muscle lies superficial to the proximal one-half of *M. ilirotrochantericus cranialis* and to the entire *ilirotrochantericus medius*. It lies deep to the aponeurosis that gives rise to *M. iliotibialis lateralis*.

M. ilirotrochantericus cranialis (Figs. 2, 3: ITCR).—The muscle arises by fleshy and tendinous fibers for about 9 mm from the ventral margin of the dorsal iliac fossa. As the fan-shaped belly extends caudoventrally, it narrows to about 4 mm to insert by fleshy fibers on the lateral surface of the femoral shaft about 8 mm from the proximal end of the greater femoral trochanter. The insertion is just deep to *M. femorotibialis externus pars proximalis*. The distal 1 mm of the insertion fuses with the origin of a few fibers of *M. femorotibialis medius*. Proximally, *M. ilirotrochantericus cranialis* lies deep to *M. ilirotrochantericus caudalis*, and, distally, it lies deep to *M. iliotibi-*

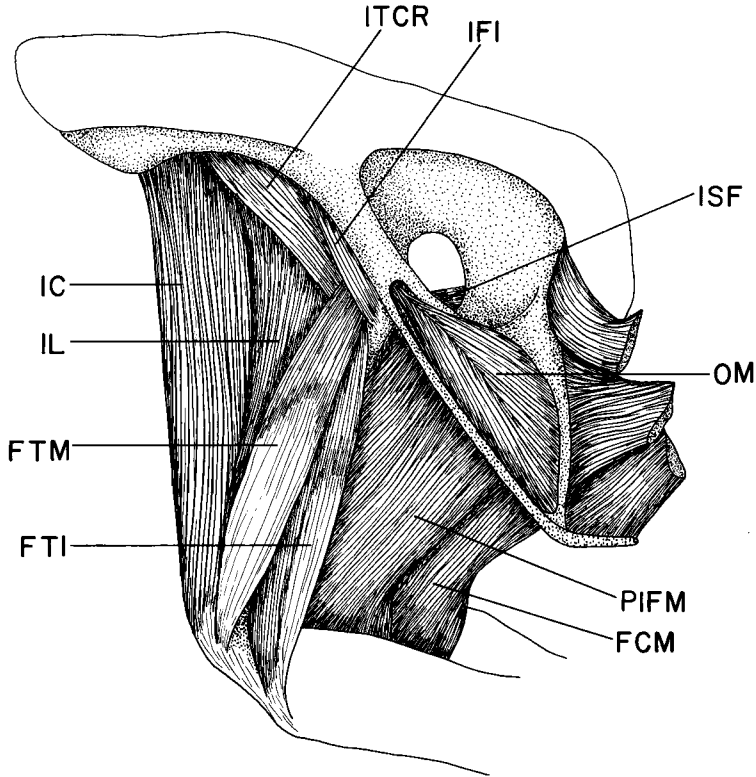


Fig. 2. Medial view of the thigh of *Amazona albifrons* showing superficial muscles. Abbreviations given in Fig. 1.

alis lateralis. It lies immediately cranial to *M. iliotrochantericus medius*.

M. iliotrochantericus medius (Fig. 4: ITM).—The muscle originates by fleshy fibers from the ventral rim of the dorsal iliac fossa for a distance of about 4 mm caudal to the origin of *M. iliotrochantericus cranialis* and superficial to that of *M. iliofemoralis internus*. The fan-shaped belly passes caudolaterally and tapers to about 2 mm. It inserts by a flat tendon on the lateral surface of the femur, just distal to the trochanter and proximal to the insertion of *M. iliotrochantericus cranialis*. *M. iliotrochantericus medius* lies deep to *M. iliotrochantericus caudalis* and just caudal to *M. iliotrochantericus cranialis*.

M. femorotibialis externus (Figs. 1, 4: FTEP).—This large, fusiform muscle occupies the caudolateral surface of the deep thigh. It and *M. femorotibialis medius* are intimately fused except at their origins, which are separated by the insertion of *M. iliotrochantericus cranialis*. Both proximal and distal heads are present. The proximal head arises by fleshy fibers from the lateral and caudolateral surfaces of the femur, extending from the area just caudal to the insertion of *M. iliotrochantericus cranialis* to the distal one-

quarter of the femur, where it fuses with the distal head. About half way down the thigh there develops a dense aponeurosis that covers both proximal and distal heads, as well as *M. femorotibialis medius*. Distally, the aponeurosis thickens and contributes to the patellar tendon. The insertion is on the patellar crest of the tibiotarsus.

The distal head is closely associated with the proximal head. It arises by fleshy fibers from the caudal surface of the femur, beginning in its distal one-half and extending for about 1 cm. Distal to this point it fuses with the proximal head and inserts as described above.

M. femorotibialis medius (Figs. 2, 4: FTM).—This well-developed muscle lies along the cranial and medial surfaces of the thigh. It arises by tendinous fibers from the medial surface of the trochanteric crest and by fleshy fibers from almost the entire length of the craniomedial surface of the femur. In its distal one-half *M. femorotibialis medius* is covered by an aponeurosis that is continuous with that of *M. femorotibialis externus*. These two muscles are fused in the distal three-quarters of their length, and the aponeurosis contributes to the patellar tendon. The belly of

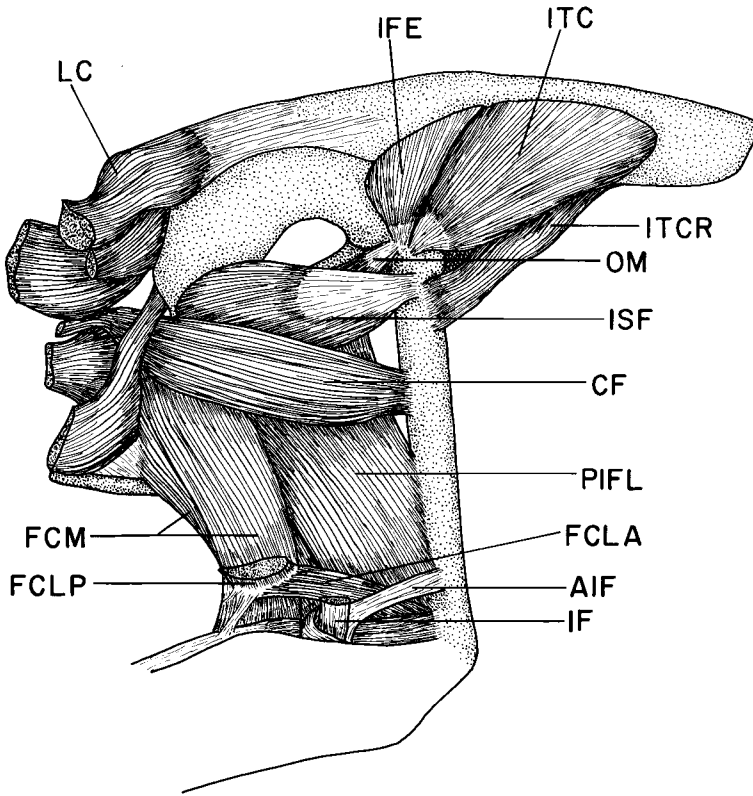


Fig. 3. Lateral view of the thigh of *Amazona albifrons* showing the deep muscles. Abbreviations given in Fig. 1. The following muscles shown in Fig. 1 have been removed: *M. femorotibialis externus pars proximalis*, *M. iliotibialis cranialis*, *M. iliofibularis*, and *M. iliotibialis lateralis*.

M. femorotibialis medius, however, inserts by fleshy fibers directly on the proximal end of the patella.

M. femorotibialis internus (Fig. 2: FTI).—This unipinnate muscle arises by fleshy fibers from the caudal and caudomedial surfaces of the femoral shaft. The origin extends from immediately distal to the insertion of *M. iliofemoralis internus* to the level of the medial supercondylar crest. The fibers insert on a narrow aponeurosis that develops along the caudal border of the muscle. The muscle crosses the femoro-tibial joint and gives rise to a stout tendon that inserts on the medial surface of the cranial cnemial crest, just deep to the origin of *M. gastrocnemius pars medialis*. The cranial border of *M. femorotibialis internus* lies deep to *M. femorotibialis medius*. The caudal border lies superficial to the insertion of *M. pubo-ischio-femoralis pars medialis*.

M. iliofibularis (Figs. 1, 3, 6, 7, 8, 9, 10, 11: IF).—This large, fan-shaped muscle lies on the lateral surface of the thigh, just cranial to *M. flexor cruris lateralis*. Its cranial one-quarter arises from the aponeurosis that covers the muscles of the dorsal iliac fossa (*Mm. iliofemoralis externus* and *iliotrochantericus caudalis*).

In one of the six specimens dissected a small slip (about 1 mm wide) originates by tendinous fibers from the femoral shaft about 2 mm below the trochanter and by fleshy fibers from the lateral surface of *M. femorotibialis externus*, just distal to the origin of this muscle. Caudally, the origin is by fleshy and tendinous fibers from the dorsolateral iliac crest to about 3 mm from the terminal process of the ilium. Cranial and caudal parts of the muscle remain separate as they pass distally down the lateral surface of the thigh, superficial to *Mm. ischiofemoralis*, *caudofemoralis*, and *pubo-ischio-femoralis*. They fuse about four-fifths of the way down the thigh and converge on a strong, cylindrical tendon that passes through the ansa iliofibularis (biceps loop) and enters the shank musculature between *pars lateralis* and *intermedius* of *M. gastrocnemius*. The insertion is on the caudal surface of the fibula.

The ansa iliofibularis consists of three arms. The proximal femoral arm arises on the caudolateral surface of the femur about three-quarters of the way down its length. This arm is about 2 mm wide, and it expands distally as it approaches the *M. iliofibu-*

laris tendon. It is about 8 mm long. The distal femoral arm and the fibular arm are less well-developed. They arise from aponeuroses on the deep surfaces of *Mm. gastrocnemius pars lateralis* and *flexor perforans et perforatus digiti II*, respectively. All three arms converge just caudal to the shank musculature and thicken to form a sling that supports the tendon of *M. iliofibularis*.

M. flexor cruris lateralis (Figs. 1, 3: FCLA and FCLP).—This large, parallel-fibered muscle lies on the lateral surface of the thigh just caudal to *M. iliofibularis*. It consists of two bellies, *pars pelvica* and *pars accessoria*. *Pars pelvica* originates by fleshy and tendinous fibers from the dorsolateral iliac crest, extending from about 2 mm caudal to the ilioischadic foramen to the terminal iliac process. Caudal to this point the origin continues from a tendon that gives rise to the ventral caudal muscles. The belly passes distally, lying superficial to the origin of *M. ischiofemoralis* and the lateral surfaces of *Mm. pubo-ischio-femoralis* and *flexor cruris medialis* and deep to the proximal part of *M. caudofemoralis*. About four-fifths of the way down the thigh the cranial one-half of *pars pelvica* inserts on a raphe that separates it from *pars accessoria*. At this point, the caudal one-half of *pars pelvica* inserts by tendinous fibers on the adjacent surface of *M. flexor cruris medialis*. *Pars accessoria* crosses the distal portion of *M. pubo-ischio-femoralis* and inserts by short, tendinous fibers on the caudal surface of the femur just deep to the origin of the femoral arm of the *ansa M. iliofibularis*. *Pars accessoria* is about 3 mm wide. As it arises from the raphe, *pars accessoria* is connected by a thin, ligamentous band to the caudal edge of *M. gastrocnemius pars intermedia*.

M. caudofemoralis (Figs. 1, 3: CF).—Only *pars caudofemoralis* is present. It originates by short, tendinous fibers on the caudolateral surface of the femur about one-third of the way down its length. As it extends caudally, it lies deep to *Mm. iliofibularis* and *femorotibialis externus* and superficial to *M. pubo-ischio-femoralis* and the caudal portion of *M. ischiofemoralis*. The strap-shaped belly passes between *Mm. flexor cruris lateralis* and *flexor cruris medialis* and inserts by a slender tendon on the aponeurosis on the ventral surface of the rectrices.

M. ischiofemoralis (Figs. 2, 3: ISF).—The muscle arises by fleshy fibers from the wing of the ischium caudal and ventral to the ilioischadic foramen, and covers the caudoventral one-half of that foramen. As the well-developed, fan-shaped belly passes cranially, an aponeurosis develops on the lateral surface. The fibers converge on the aponeurosis as it narrows to form a tendon about 3 mm wide. The insertion is on the lateral surface of the femur at the level of insertion of *M. ilirotrochantericus cranialis*. *M. ischiofemoralis* lies deep to *Mm. iliofibularis* and *caudofemoralis* and superficial to the origin of *M. pubo-ischio-femoralis*.

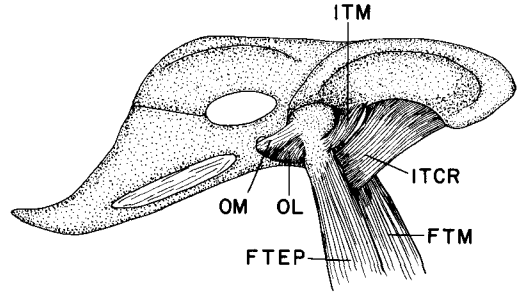


Fig. 4. Lateral view of the upper thigh and central pelvis of *Amazona albifrons* showing deep muscles. Abbreviations given in Fig. 1. The following muscles shown in Fig. 3 have been removed; *M. caudofemoralis*, *M. iliofemoralis externus*; *M. ilirotrochantericus caudalis*, *M. ilirotrochantericus cranialis*, and *M. ischiofemoralis*.

M. flexor cruris medialis (Figs. 1, 2, 3: FCM).—The muscle arises by fleshy and tendinous fibers from the caudal one-third of the lateral surface of the wing of the ischium and from the dorsal margin of the membrane covering the ischiopubic foramen. As the large, parallel-fibered belly extends distally, its cranial margin lies superficial to *M. pubo-ischio-femoralis pars medialis* and deep to *M. flexor cruris lateralis*. About four-fifths of the way down the thigh, the muscle receives the tendinous insertion of *M. flexor cruris lateralis pars pelvica*. The muscle crosses to the medial surface of the shank and gives rise to a strong tendon, about 3 mm wide. The tendon enters the shank musculature between *pars medialis* and *intermedia* of *M. gastrocnemius* and inserts on the caudo-medial surface of the tibiotarsus, just distal to the insertion of *M. pubo-ischio-femoralis pars medialis*. About 4 mm proximal to its tendon, *M. flexor cruris medialis* is connected to *M. flexor cruris lateralis* as the latter gives rise to its accessory head.

M. pubo-ischio-femoralis (Figs. 2, 3: PIFL, PIFM).—The muscle arises by fleshy and tendinous fibers from the ventrolateral margin of the ischium, extending from the caudal border of the obturator foramen to about 6 mm from the terminal process of the ischium. The origin lies dorsal to the ischiopubic fenestra and superficial to the membrane that covers it. Although the fibers of *pars lateralis* and *medialis* are fused at their origin, the two bellies are distinguishable. *Pars medialis* extends caudally beyond *pars lateralis* for about 4 mm. The cranial two-thirds of *pars medialis* arises by an aponeurosis from the deep surface of *pars lateralis*. Both bellies are parallel-fibered, and they extend downward in a slightly cranial direction, passing deep to *Mm. iliofibularis* and *flexor cruris lateralis*. *Pars lateralis* inserts by fleshy fibers on the caudal surface of the femur, extending from about the midpoint of the shaft to the level of the *ansa M.*

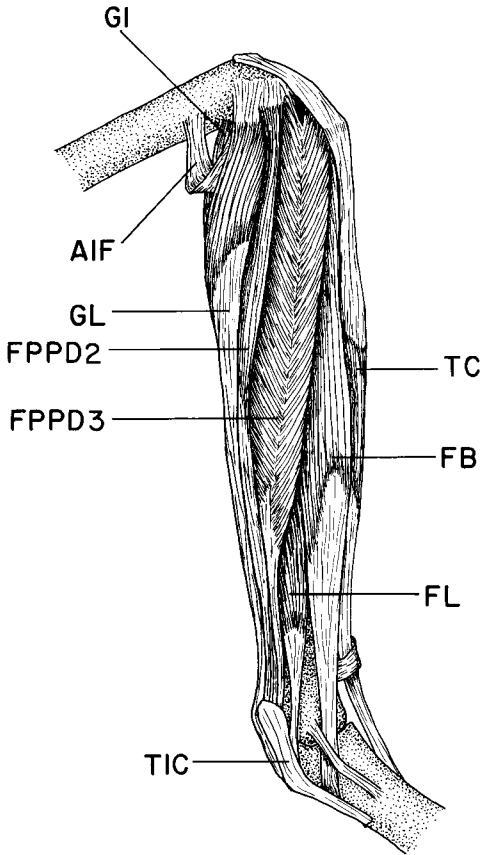


Fig. 5. Lateral view of the shank of *Amazona albifrons* showing superficial muscles. Note the relatively large fibularis brevis and absence of the long tendon of insertion of *M. fibularis longus*. Abbreviations for Figs. 5-11: AIF, ansa *M. iliofibularis*; EDL, *M. extensor digitorum longus*; FB, *M. fibularis brevis*; FDL, *M. flexor digitorum longus*; FHL, *M. flexor hallucis longus*; FL, *M. fibularis longus*; FPD2, *M. flexor perforatus digiti II*; FPD3, *M. flexor perforatus digiti III*; FPD4, *M. flexor perforatus digiti IV*; FPPD2, *M. flexor perforans et perforatus digiti II*; FPPD3, *M. flexor perforans et perforatus digiti III*; GI, *M. gastrocnemius pars intermedius*; GL, *M. gastrocnemius pars lateralis*; GM, *M. gastrocnemius pars medialis*; TC, *M. tibialis cranialis*; TCF, *M. tibialis cranialis caput femorale*; TIC, tibial cartilage.

iliofibularis. The caudal one-third of its fibers turn medially to insert on an aponeurosis on the caudal surface of the proximal end of *M. gastrocnemius pars medialis*. The cranial one-half of pars medialis inserts by tendinous fibers on the caudomedial surface of the femoral shaft for the 5 mm proximal to the me-

dial condyle. The caudal one-half inserts on the aponeurosis of *M. gastrocnemius pars medialis*, just medial to *M. pubo-ischio-femoralis pars lateralis*.

M. obturatorius lateralis (Fig. 4: OL).—Only the ventral head is present. This short, parallel-fibered muscle arises from the pubis just cranial to the obturator foramen, and from the cranial and ventral rim of the obturator foramen. It extends laterally, just ventral to the tendon of *M. obturatorius medialis*, and inserts on the caudal surface of the femur about 2 mm distal to the trochanter.

M. obturatorius medialis (Figs. 2, 3, 4: OM).—This well-developed, fan-shaped muscle lies on the medial surface of the synsacrum. It originates from the entire wing, as well as the caudal part of the body of the ischium, from the membrane across the ischio-pubic fenestra, and from the dorsal margin of the pubis from the obturator foramen to about 6 mm from the apex of the pubis. The fibers pass cranially, converging on a central tendon that forms about one-half way along the length of the muscle. As the muscle approaches the obturator foramen the tendon thickens and passes to the lateral surface of the muscle. Fibers continue to insert on the tendon as it extends through the obturator foramen to insert on the caudolateral surface of the femoral trochanter just caudal to the insertion of *M. iliofemoralis externus*.

M. iliofemoralis internus (Fig. 2: IFI).—This small, band-like muscle arises by fleshy fibers from the ventral margin of the ilium for a distance of about 3 mm from the acetabulum. It extends caudodistally to insert on the medial surface of the femur just distal to the attachment of the articular capsule of the hip joint. *M. iliofemoralis internus* passes medial to *Mm. ilioprochantericus cranialis* and *femorotibialis medius*.

M. iliofemoralis externus (Fig. 3: IFE).—This small, fan-shaped muscle arises by fleshy fibers from the caudodorsal corner of the dorsal iliac fossa immediately caudal to *M. ilioprochantericus caudalis*. It lies deep to the aponeurosis that gives rise to *M. ilioprotibialis lateralis*. The muscle extends across the proximal end of the femur and gives rise to a short, flat tendon that inserts on the lateral surface of the trochanter between the insertions of *Mm. ilioprochantericus caudalis* and *obturatorius medialis*.

M. gastrocnemius (Figs. 5, 10: GI, GL, GM).—Pars lateralis arises by a strong, flat tendon from the lateral epicondyle of the femur. The spindle-shaped belly extends about two-fifths of the way down the caudolateral surface of the shank. Here, the fibers insert on an aponeurosis that has developed on the lateral surface of the belly. The aponeurosis contributes to a tendon of insertion shared with pars intermedia and medialis. This very strong tendon crosses the tibial cartilage and inserts on the proximal end of the hypotarsus, merging with an aponeurosis that covers the plantar surface of the tarsometatarsus. Pars

lateralis is the most caudal of the shank muscles. It lies superficial to *M. flexor perforans et perforatus digiti II*.

Pars intermedia lies just medial to *M. flexor hallucis longus*. It arises by tendinous fibers from the caudal surface of the medial femoral condyle. The strap-shaped, parallel-fibered belly extends distally as the most superficial muscle on the caudomedial surface of the shank. About one-half way down the shank the fibers insert on a broad aponeurosis that fuses with that of *pars lateralis* and *medialis* to form the common tendon of insertion.

Pars medialis is the most superficial muscle on the medial shank. It arises by fleshy and tendinous fibers from the cranial cnemial crest and the medial femoral condyle, by fleshy fibers from the aponeurosis covering the proximal one-half of the medial surface of *M. tibialis cranialis*, and from a line along the medial surface of the proximal one-half of the femoral shaft. The belly is unipinnate, the fibers inserting on a dense aponeurosis that covers the medial surface of the muscle. The aponeurosis fuses with those of *pars lateralis* and *pars intermedia* about one-half way down the shank to form the common tendon of insertion. The belly of *pars medialis* extends to about 7 mm from the distal end of the tibiotarsus.

M. tibialis cranialis (Figs. 5, 6, 10: TC, TCF).—This is the most cranial muscle of the shank. There are two heads, a superficial, or tibial, and a deep, or femoral.

The tibial head is, by far, the larger. It arises by fleshy and tendinous fibers from the entire cranial cnemial crest, from the patellar ligament, and from the cranial edge of the proximal 5 mm of *M. fibularis longus*. A few fleshy fibers arise from the underlying femoral head, as well as from *M. extensor digitorum longus*. The fusiform belly extends down the shank, superficial to these two muscles.

The femoral head arises by a flat tendon from the cranial surface of the lateral femoral condyle just beneath the patellar tendon. It extends for about 3 mm across the femorotibial joint and gives rise to a rather slender, parallel-fibered belly. When the patellar tendon is removed, the tendon and proximal part of the belly are visible between the two heads of *M. flexor perforans et perforatus digiti III*. The femoral head extends distally, lying deep to *M. flexor perforans et perforatus digiti III* and superficial and lateral to *M. extensor digitorum longus*. About one-third of the way down the shank an aponeurosis develops on the craniolateral surface of the muscle. This fuses with an aponeurosis of the tibial head. Just distal to this point the tibial head divides to form two discrete heads, a deep and a superficial. The femoral head is included in the deep head. Each of the two heads gives rise to a separate tendon. In five of the six specimens the tendons fuse just proximal to the retinaculum extensorium tibiotarsi on the cranial surface of the tibiotarsus. As it passes through the retinaculum,

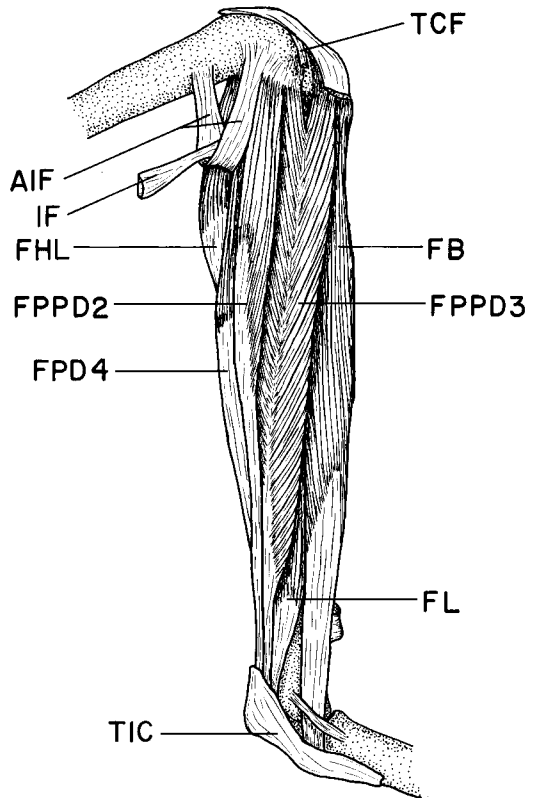


Fig. 6. Lateral view of the shank of *Amazona albifrons* showing deep muscles. Abbreviations given in Fig. 5. The following muscles shown in Fig. 5 have been removed: *M. gastrocnemius pars lateralis* and *M. tibialis cranialis*.

the tendon lies superficial to that of *M. extensor digitorum longus*. The tendon inserts on a small tuberosity on the craniomedial surface of the tarsometatarsus about 6 mm from the proximal end of this bone. In one specimen the two tendons remain entirely separate to their point of insertion, which is as described above.

M. extensor digitorum longus (Figs. 11, 13, 14, 16: EDL).—The muscle lies on the cranial surface of the shank, deep to *M. tibialis cranialis* and medial to *M. fibularis longus*. It arises by fleshy fibers from the entire lateral cnemial crest and the cranial and lateral surfaces of the proximal one-third of the tibiotarsus. The bipinnate belly extends distally to the retinaculum extensorium tibiotarsi (about 7 mm from the distal end of the tibiotarsus), its fibers inserting on a conspicuous tendon that develops on its craniolateral surface. The tendon passes through the retinaculum, deep to the tendon of *M. tibialis cranialis*, and then

beneath the supratendinal bridge, which is unossified. As the tendon crosses the intertarsal joint, it passes through a cartilaginous pad that covers the medial condyle of the tibiotarsus. The tendon passes through the retinaculum extensorium tarsometatarsi on the dorsomedial corner of the proximal end of the tarsometatarsus, and immediately distal to this point it sends a branch to the hallux. The main tendon continues on to the dorsal surface of the foot and sends branches to each of the remaining three digits.

The branch to the hallux turns onto the medial surface of the tarsometatarsus and passes through a retinaculum on the first metatarsal and through another on the dorsal surface of the proximal end of the first phalanx of the hallux. The tendon then extends along the dorsal surface of the first phalanx, crosses the interphalangeal joint, and expands slightly as it inserts on the base of the second phalanx. An elastic band originates from the dorsal surface of the first phalanx about two-thirds of the way down its length and extends to the deep surface of the tendon at its insertion.

About two-thirds of the way down the dorsal surface of the tarsometatarsus the main tendon bifurcates. The medial division extends toward digit II. Before crossing the metatarsal-phalangeal joint, it gives rise to two broad, lateral extensions that contribute to the branches of the lateral division. The tendon extends on to the dorsal surface of digit II and passes through a retinaculum on the base of the first phalanx. The retinaculum is partially composed of fibers from the lateral division. The tendon crosses the dorsolateral surface of the first interphalangeal joint and has lateral and medial attachments on the base of the second phalanx. It continues down the dorsal surface of the second phalanx, crosses the second interphalangeal joint, and inserts on the base of the third phalanx in the same manner as the tendon to digit I. An elastic band is present. A small, accessory tendon extends from the retinaculum on the base of digit II along the dorsal surface of the first phalanx and inserts on the base of the second phalanx with the main tendon to this digit.

The lateral division bifurcates at the base of digit IV. One branch extends toward digit III. As it crosses the dorsolateral surface of the metatarsal-phalangeal joint, it receives the most proximal of the two broad extensions of the medial division. Immediately distal to this point, the tendon passes through a sheath formed by an extension from digit IV and the more distal of the broad extensions from the medial division. The sheath gives rise to three accessory tendons that will be discussed subsequently.

The main tendon to digit III crosses the dorsolateral surfaces of the first and second interphalangeal joints. It has attachments at the bases of both phalanges, like those of the tendon to digit II. As it approaches the distal end of the third phalanx, the tendon turns onto the dorsal surface and fuses with two

of the three accessory tendons. The insertion, on the base of the terminal phalanx, is similar to those of digits I and II. No elastic band is present. The medial accessory tendon to digit III arises from the sheath about one-quarter of the way down the dorsal surface of the first phalanx. It crosses to the medial surface of the digit, and has attachments around the ventral surface of the first and second interphalangeal joints. It merges with the main tendon on the dorsal surface of the third digit, as described.

The middle accessory tendon to digit III extends from the distal end of the sheath to the base of the second phalanx. Here, it expands and inserts. The lateral accessory tendon is the most slender of the three. It arises from the lateral margin of the sheath and extends along the lateral surface of the third digit. As it crosses the first and second interphalangeal joints, it has attachments to the main tendon. It merges with the main tendon on the dorsal surface of the distal end of the third phalanx.

The most lateral division of the extensor digitorum longus tendon extends toward digit IV. As it passes along the base of the first phalanx it passes through a sheath, which is joined to that of digit III. This sheath gives rise to two accessory tendons that will be discussed subsequently. The main tendon passes along the dorsal surface of the digit, beneath a retinaculum on the base of each of the proximal four phalanges. It expands to insert on the dorsal surface of the base of the fifth phalanx. No elastic band is present.

The medial accessory tendon to digit IV extends along the dorsal surface of digit IV, just medial to the main tendon. It crosses the first and second interphalangeal joints and inserts on the base of the third phalanx just deep to the retinaculum for the main tendon. The lateral accessory tendon to digit IV lies lateral to the main tendon along the most proximal phalanx. From its attachment at the base of the second phalanx it extends to the lateral surface of the digit. After crossing the third interphalangeal joint, it passes dorsally to merge with the main tendon on the distal end of the fourth phalanx.

M. fibularis brevis (Figs. 5, 6, 11: FB).—This well-developed muscle lies on the cranial surface of the shank, lateral to *M. tibialis cranialis*. There are two heads of origin. The proximal, superficial head begins its origin at the tip of the lateral cnemial crest along with that of *M. flexor perforans et perforatus digiti III*. About 8 mm distal to this point, a smaller, deep head arises by fleshy fibers from the lateral surface of the tibiotarsus and cranial surface of the fibula. It extends for about 7 mm and fuses with the superficial head. The origin of the superficial head continues distally from an aponeurosis that separates it from *M. flexor perforans et perforatus digiti III* and from the craniolateral surface of the fibula to the level of the retinaculum *M. fibularis*. A dense aponeurosis develops on the lateral surface of the muscle in its

distal one-half and gives rise to a strong tendon. As the tendon crosses the lateral surface of the intertarsal joint, it is held in place by a ligament that spans the joint. It turns to the plantar surface and inserts on the lateral margin of the hypotarsus.

M. fibularis longus (Figs. 5, 6: FL).—This rather poorly developed muscle lies along the distal one-third of the lateral surface of the shank, caudal to *M. fibularis brevis* and cranial to *M. flexor perforans et perforatus digiti III*. It arises from the cranial edge of the distal 1 cm of the aponeurosis that separates *M. fibularis brevis* from *M. flexor perforans et perforatus digiti III*. The unipinnate belly extends distally, the fibers inserting on an aponeurosis that develops on its caudal surface. About 8 mm from the distal end of the tibiotarsus the aponeurosis gives rise to a thin, flat tendon. The tendon turns caudally to insert on the proximolateral corner of the tibial cartilage. The long tendon of insertion, described in some birds (George and Berger 1966), is absent.

M. flexor perforans et perforatus digiti III (Figs. 5, 6, 7, 10, 15: FPPD3).—The muscle lies on the lateral surface of the shank, just caudal to *M. fibularis brevis* and cranial to *M. flexor perforans et perforatus digiti II*. There are two heads of origin. The cranial head arises by fleshy fibers from the lateral surface of the patellar ligament and from the lateral cnemial crest. The caudal head arises from the head of the fibula and from the underlying *M. flexor perforatus digiti III*. The two heads fuse about 4 mm distal to their origin. As the bipinnate belly extends distally, fibers continue to arise from the shaft of the fibula and the aponeuroses that separate the muscle from *M. flexor perforans et perforatus digiti II* and from *Mm. fibularis longus* and *brevis*. About 1 cm from the distal end of the tibiotarsus the belly gives rise to a strong, cylindrical tendon. It passes through the tibial cartilage as the most superficial and lateral of the flexor tendons. As it crosses the intertarsal joint, it lies medial to the tendon of *M. flexor perforatus digiti IV* in a sheath formed by *M. flexor perforatus digiti III* (Figs. 7 and 10). It remains the most superficial tendon as it passes along the plantar surface of the foot, lying just medial to the tendon of *M. flexor perforatus digiti IV*. The tendon crosses the third metatarsal-phalangeal joint, and about one-third of the way down the proximal phalanx it perforates the tendon of *M. flexor perforatus digiti III*. The tendon is held in place by ligamentous bands on the bases of the first two phalanges. About one-half way down the second phalanx the tendon of *M. flexor perforans et perforatus digiti III* is perforated by the branch of *M. flexor digitorum longus* to this digit. The resulting two branches insert on lateral and medial surfaces, respectively, of the base of the third phalanx.

The hypotarsus in this species consists of a superficial and deep compartment. The superficial compartment is defined by two vertical ridges. The deep compartment is a bony tunnel. Only *Mm. flexor dig-*

itorum longus and *flexor hallucis longus* pass through the tunnel.

M. flexor perforans et perforatus digiti II (Figs. 5, 6, 7, 11, 15: FPPD2).—This muscle lies on the lateral surface of the shank just caudal to *M. flexor perforans et perforatus digiti III* and cranial to *M. gastrocnemius pars lateralis*. It arises by tendinous fibers from the distal end of the lateral femoral condyle and the head of the fibula and by fleshy fibers from the lateral (distal) arm of the ansa *M. iliofibularis*. In its proximal one-third, it is fused with the belly of *M. flexor perforans et perforatus digiti III*. As the bipinnate belly extends down the shank, it lies superficial to *M. flexor perforatus digiti IV*. About three-fifths of the way down the shank the muscle tapers to a flat tendon. The tendon turns to the caudal surface of the shank and passes through the tibial cartilage medial to and in the same plane as the tendon of *M. flexor perforans et perforatus digiti III*. It extends along the plantar surface of the foot and crosses under the tendon of *M. flexor perforatus digiti II* but never penetrates it. The tendon crosses the metatarsal-phalangeal joint of digit II and extends along the first phalanx, superficial to the branch of the flexor digitorum longus tendon to this digit. It crosses the first interphalangeal joint and inserts on the medial surface of the base of the second phalanx. It is not penetrated by the branch tendon of *M. flexor digitorum longus* to this digit.

In one of the six specimens dissected, this muscle splits into two distinct heads about 8 mm distal to its origin. Each head gives rise to a separate tendon. They fuse about 8 mm from the distal end of the tibiotarsus.

M. flexor perforatus digiti IV (Figs. 6, 7, 10, 15: FPD4).—The muscle lies on the caudolateral surface of the shank, deep to *Mm. flexor perforans et perforatus digiti II* and *III* and superficial to *M. flexor perforatus digiti III*. There are two heads of origin. The proximal head arises from the caudal surface of the lateral femoral condyle and from the lateral surface of the aponeurosis that gives rise to *M. flexor perforatus digiti III*. The distal head arises from this aponeurosis and by long tendinous fibers from the distal arm of the ansa *M. iliofibularis*. The two heads fuse about one-third of the way down the tibiotarsus. Fibers continue to arise from the aponeurosis to about the level of origin of the distal head of *M. flexor perforatus digiti III*. Distal to this point the muscle tapers to a broad, flat tendon. It passes through the tibial cartilage deep to the tendons of *Mm. flexor perforans et perforatus digiti II* and *flexor perforatus digiti III* and medial to that of *M. flexor perforans et perforatus digiti III*. It passes through a superficial compartment in the hypotarsus with the tendons of *Mm. flexor perforans et perforatus digiti II* and *III*. As the tendon approaches the distal end of the tarsometatarsus it enters a cartilaginous compartment on the trochlea of the fourth metatarsal. It crosses

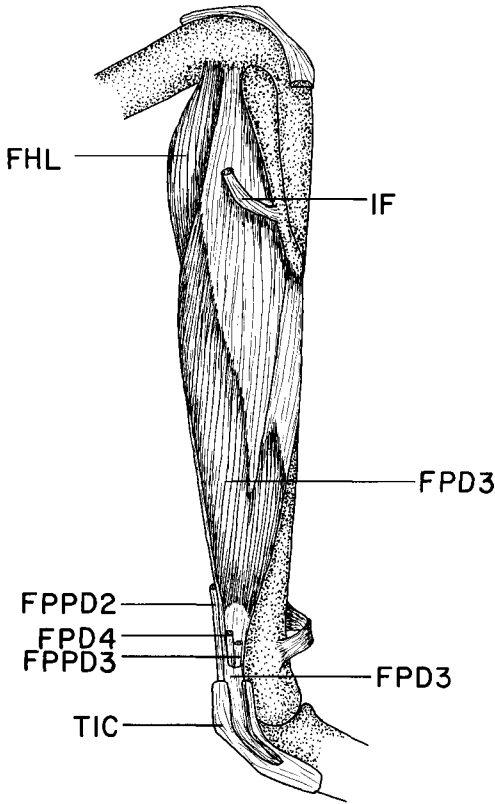


Fig. 7. Lateral view of the shank of *Amazona albifrons* showing deep muscles. Note the sheath formed by the tendon of *M. flexor perforatus digiti III*. Abbreviations given in Fig. 6 have been removed: *M. fibularis brevis*, *M. fibularis longus*, *M. flexor perforatus digiti IV*, *M. flexor perforans et perforatus digiti II*, *M. flexor perforans et perforatus digiti III*, and *M. tibialis cranialis*. The tibial cartilage has been cut open.

the metatarsal-phalangeal joint and turns caudally to lie along the plantar surface of the fourth digit superficial to the branch of *M. flexor digitorum longus* to this digit. The tendon is held in place by ligamentous sheaths at the bases of the second and third phalanges. The tendon also sends a strong branch to the lateral surface of the base of the second phalanx. At the proximal end of the third phalanx the tendon is perforated by the branch of the flexor digitorum longus tendon. The lateral branch inserts on the lateral surface of the base of the third phalanx. The medial branch inserts on the medial surface of the base of the fourth phalanx.

M. flexor perforatus digiti III (Figs. 7, 8, 9, 11, 15: FPD3).—The muscle has two heads of origin. The proximal, and larger, head arises from a broad aponeurosis beginning in the intercondylar area of the

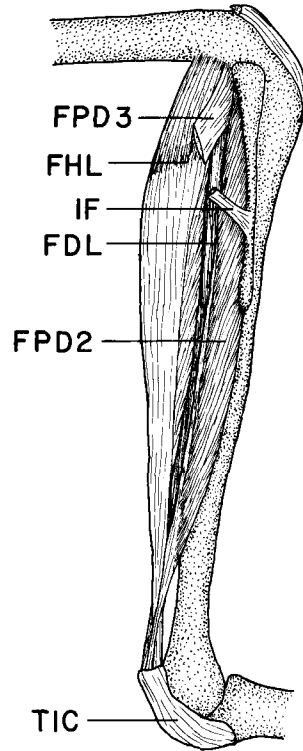


Fig. 8. Lateral view of the shank of *Amazona albifrons* showing deep muscles. Abbreviations given in Fig. 5. *M. flexor perforatus digiti III*, shown in Fig. 7, has been removed.

femur and extending on to the head of the fibula and to a level just distal to the insertion of *M. iliofibularis*. This aponeurosis continues distally, lying superficial to *M. flexor perforatus digiti II* and providing a surface of origin for *M. flexor perforatus digiti IV*. The belly of the proximal head of *M. flexor perforatus digiti III* develops along the caudal margin of this aponeurosis in the distal three-quarters of the shank. The fibers insert on a tendon that develops along the caudal surface of the distal one-half of the belly.

The distal head of *M. flexor perforatus digiti III* arises by long, tendinous fibers from the fibula adjacent to the distal interosseus foramen. The fusiform belly extends from the distal one-half of the tibiotarsus, and fuses with the proximal belly about 1.4 cm from the distal end of this bone. As the single belly approaches the tibial cartilage, it gives rise to two flat tendons, corresponding to the originally separate heads, that are joined by a thin but substantial layer of connective tissue. Together, the two tendons form a sheath around those of *Mm. flexor perforans et perforatus digiti III* and *flexor perforatus digiti IV* as they all pass through the tibial cartilage and the hy-

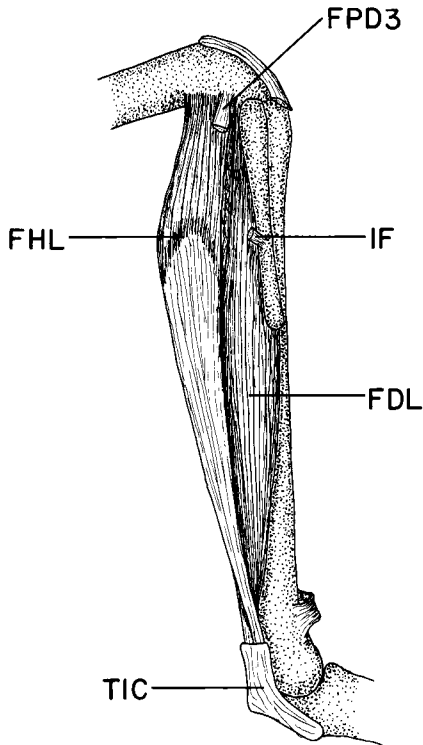


Fig. 9. Lateral view of the shank of *Amazona albifrons* showing deep muscles. Abbreviations given in Fig. 5. *M. flexor perforatus digiti II*, shown in Fig. 8, has been removed.

potarsus. The sheath lies lateral to the tendon of *M. perforans et perforatus digiti II*. Just distal to the hypotarsus the sheath narrows to a single tendon that extends toward digit III. It is held in place by ligamentous bands on the third metatarsal trochlea and on the base of the first phalanx. Immediately after crossing the third metatarsal-phalangeal joint, the tendon is perforated by that of *M. flexor perforans et perforatus digiti III* and by that of *M. flexor digitorum longus* to this digit. The lateral and medial divisions thus formed insert on the lateral and medial surfaces, respectively, of the base of the second phalanx.

M. flexor perforatus digiti II (Figs. 8, 15: FPD2).—This rather poorly developed muscle lies deep to *M. flexor perforatus digiti III* along the caudal surface of the fibula and superficial to *M. flexor hallucis longus*. There is no femoral origin, as described in other birds. The single head originates by fleshy fibers from the entire caudal surface of the fibula and distal to this from a raphe that separates the muscle from the cranial margin of *M. flexor hallucis longus*. About 9 mm from the distal end of the tibiotarsus *M. flexor perforatus digiti II* gives rise to a tendon that enters one

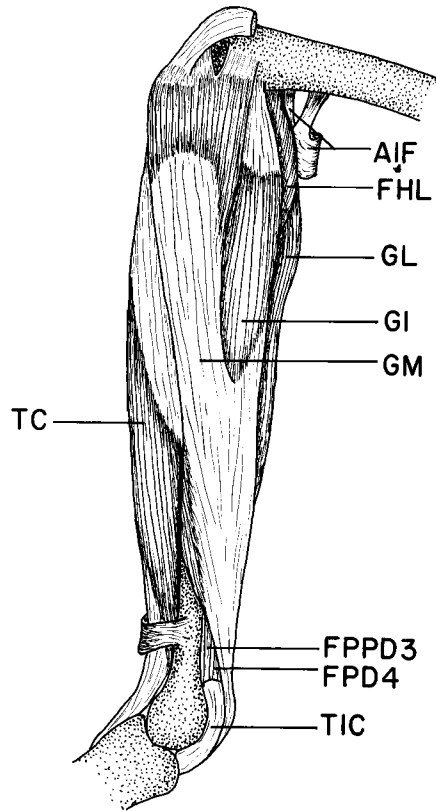


Fig. 10. Medial view of the shank of *Amazona albifrons* showing superficial muscles. Abbreviations given in Fig. 5.

of the superficial compartments in the tibial cartilage. The tendon lies medial to and on the same plane as the *M. flexor perforatus digiti III* sheath. After crossing the intertarsal joint, the tendon passes through the hypotarsus as the most medial of the flexor tendons. About one-half way down the tarsometatarsus, the tendon crosses superficial to that of *M. flexor perforans et perforatus digiti II*, coming to lie lateral to it. It crosses the second metatarsal-phalangeal joint and inserts on the lateral surface of the base of the first phalanx of this digit.

M. flexor hallucis longus (Figs. 6, 7, 8, 9, 10, 11, 12, 15: FHL).—This very well-developed muscle lies on the caudal surface of the shank deep to *M. gastrocnemius*. The single head has two origins, by tendinous fibers from just proximal to the intercondylar area of the femur, and by short, tendinous fibers from the caudal part of the knee joint capsule and medial semilunar cartilage. As the fusiform belly extends distally, a dense aponeurosis develops on its entire caudal surface. The belly ends about 1.2 cm from the distal end of the tibiotarsus. A strong, flat tendon arising from the aponeurosis passes through a deep

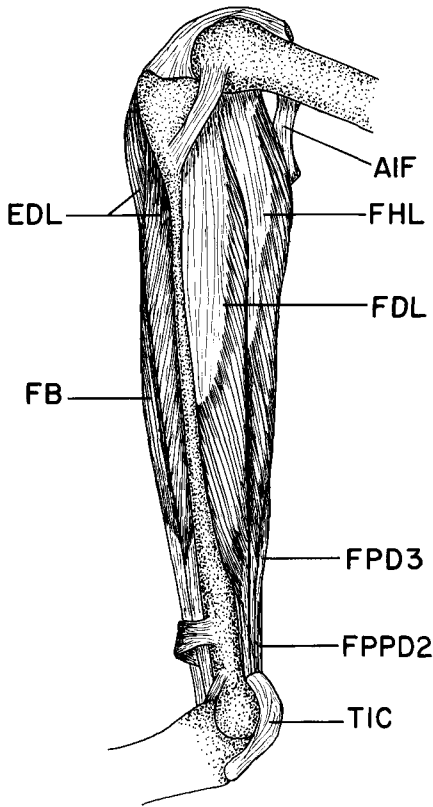


Fig. 11. Medial view of the shank of *Amazona albifrons* showing deep muscles. Abbreviations given in Fig. 5. The following muscles shown in Fig. 10 have been removed: *M. gastrocnemius pars intermedia*, *M. gastrocnemius pars medialis*, and *M. tibialis cranialis*.

compartment in the tibial cartilage, lateral to the tendon of *M. flexor digitorum longus*.

In two of the six specimens there is a minute distal head that originates from the caudal joint capsule and extends along the cranial margin of the proximal head to fuse with it about 1 cm distal to the proximal end of the tibiotarsus.

M. flexor digitorum longus (Figs. 8, 9, 11, 12, 15: FDL).—This unipinnate muscle is the deepest muscle on the caudal surface of the shank. There are two heads of origin. The lateral head arises by fleshy fibers from the caudomedial surface of the fibula for the entire length of this bone. The medial head arises by fleshy and tendinous fibers from the caudomedial surface of the tibiotarsus, from the proximal end of this bone to the level of the distal end of the body of the fibula. Distal to this point the two heads fuse, and their fibers insert on a raphe corresponding to

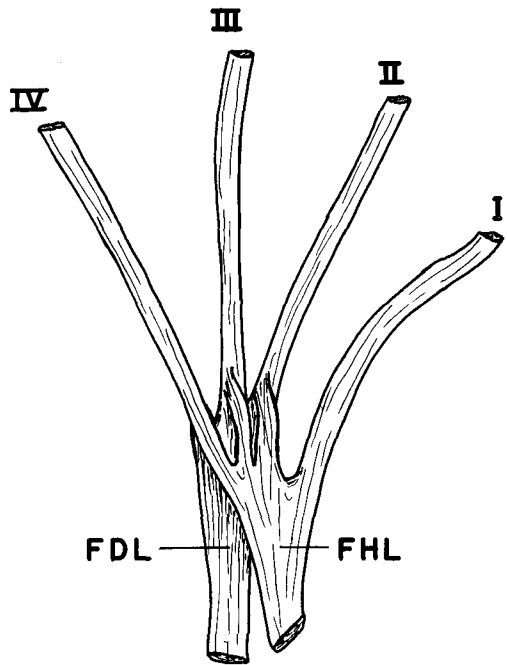


Fig. 12. Dorsal view of the flexor hallucis longus-flexor digitorum longus tendons of *Amazona albifrons*. The relationship is that of Type X of Gadow's classification, rather than Type I, as has previously been described in the Psittaciformes. Abbreviations are given in Fig. 5.

their original boundaries. About 1 cm from the distal end of the tibiotarsus the belly ends, and the raphe continues as the tendon of insertion.

Tendon of Mm. flexor hallucis longus and flexor digitorum longus (Fig. 12: FHL, FDL).—The tendons remain separate to about one-half way down the surface of the tarsometatarsus, that of *M. flexor digitorum longus* lying deep to that of *M. flexor hallucis longus*. At this point, the flexor hallucis longus tendon splits into four branches, one extending to each of the digits. The flexor digitorum longus tendon splits into three branches, to digits II, III, and IV. Each fuses with its corresponding branch of *M. flexor hallucis longus* and extends toward its digit. As the tendons extend along the caudal surfaces of their digits, they pass through ligamentous rings at each interphalangeal joint, each inserting on the base of the most distal phalanx. These are the deepest of the flexor tendons to each digit.

The branch to the hallux has a vinculum extending from its deep surface about one-half way down the length of the first phalanx to the connective tissue on the distal end of this digit. The branches to digits II, III, and IV have vincula attaching them to the

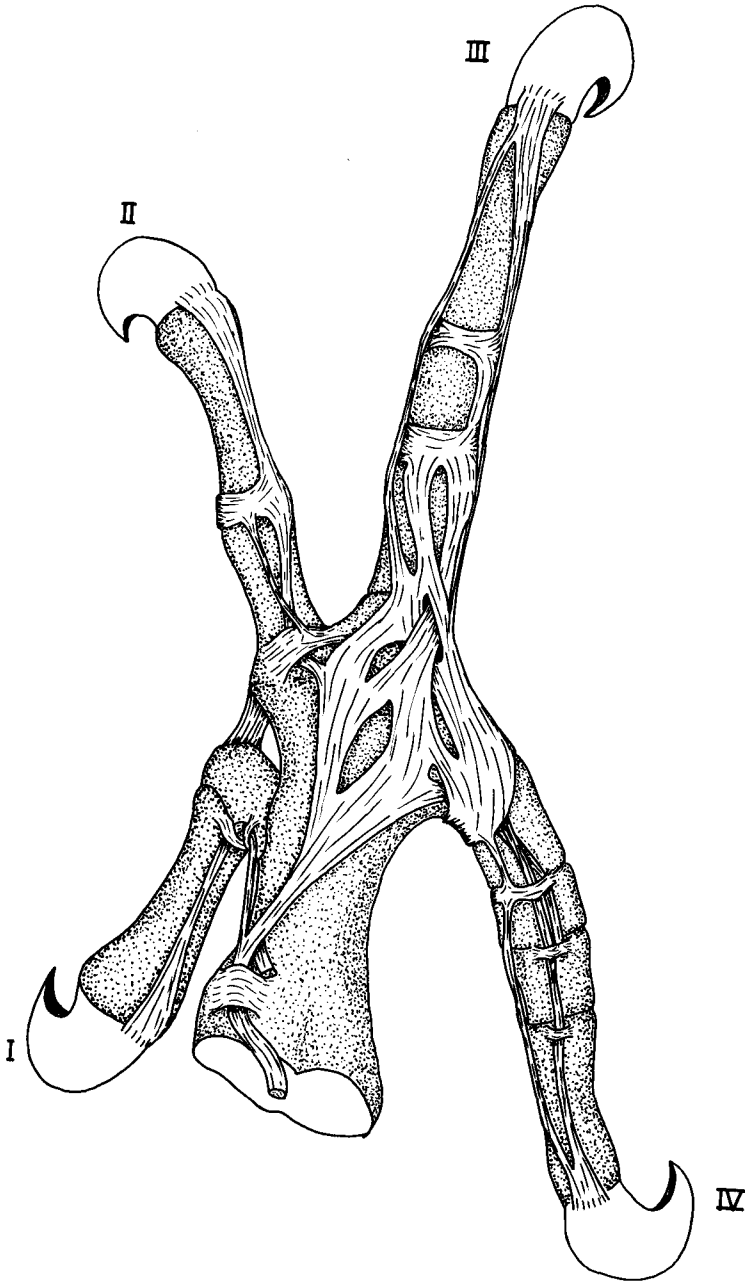


Fig. 13. Dorsal view of the foot of *Amazona albifrons* showing the divisions of the tendon of *M. extensor digitorum longus*. Note the branch to the hallux, a character otherwise known only in the Coliiformes.

penultimate phalanges of their respective digits in a manner similar to that seen in digit I.

M. flexor hallucis brevis (Fig. 15: FHBD, FHBP).— This is a very well-developed muscle on the caudo-medial surface of the tarsometatarsus. There are two

heads. The larger, proximal head has an extensive origin by fleshy fibers from the distal end of the hypotarsus, caudomedial surface of the proximal one-half of the tarsometatarsus, and deep surface of the plantar aponeurosis adjacent to the hypotarsus. The

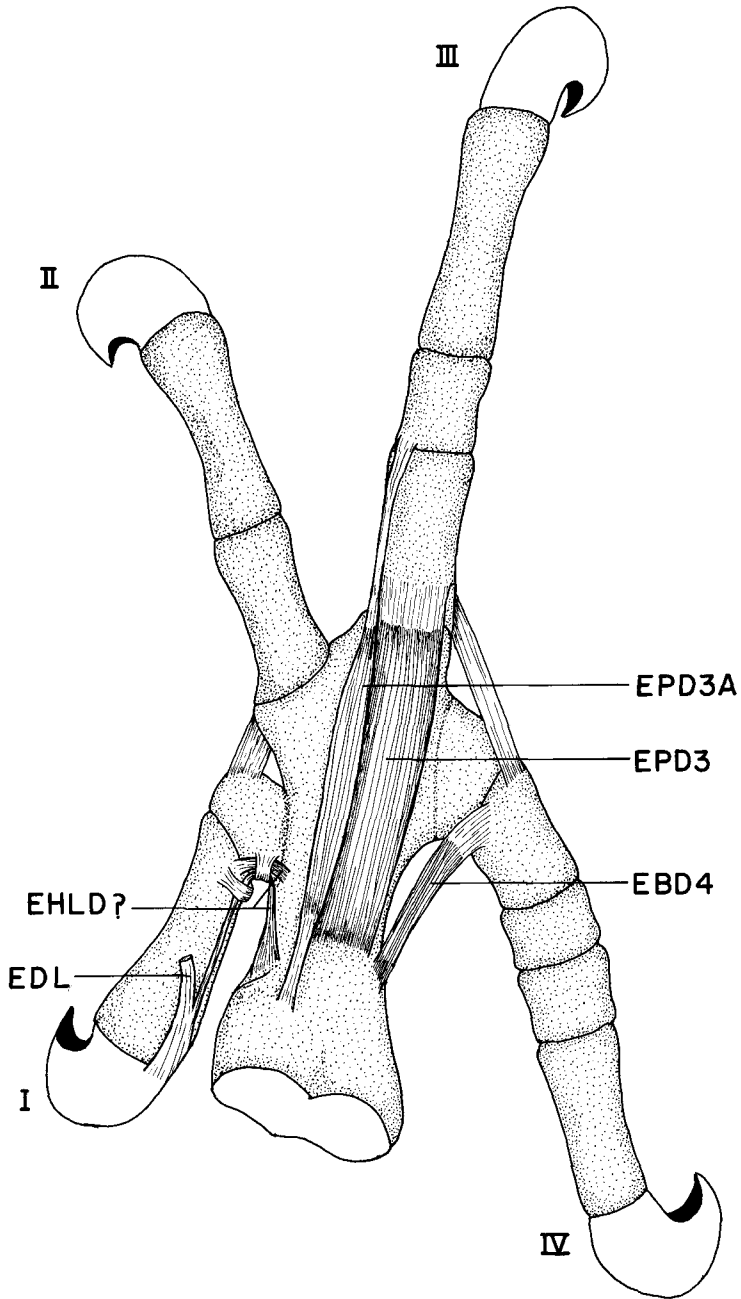


Fig. 14. Dorsal view of the foot of *Amazona albifrons*, with the extensor digitorum longus tendon removed. M. extensor hallucis longus has a distal tendon joining that of M. extensor digitorum longus. It is uncertain whether both pars proximalis and distalis of M. extensor hallucis longus are present or if both bellies correspond to pars distalis. M. extensor proprius digiti III accessorius has not been previously described in birds. Note that the caudal direction of digit IV results in M. extensor brevis digiti IV acting more as an adductor than an extensor of this digit. Abbreviations for Figs. 13-15: ABD4, M. abductor digiti IV; EBD4, M. extensor brevis digiti IV; EDL, M. extensor digitorum longus; EHLDP, M. extensor hallucis longus pars distalis; EHLPP, M. extensor hallucis longus pars proximalis; EPD3, M. extensor proprius digiti III; EPD3A, M. extensor proprius digiti III accessorius; FHBD, M. flexor hallucis brevis pars distalis; FHBP, M. flexor hallucis brevis pars proximalis; LM, M. lumbricalis. Other abbreviations given in Fig. 5.

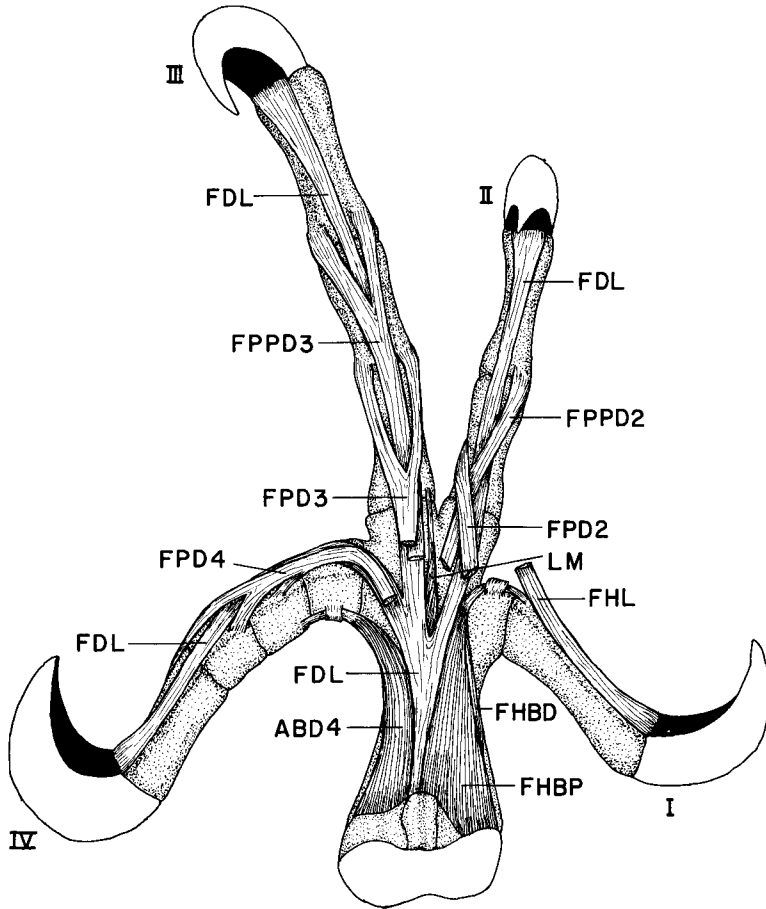


Fig. 15. Plantar view of the foot of *Amazona albifrons* showing intrinsic muscles and insertions of flexor tendons. Abbreviations given in Figs. 5 and 14. Retinacula of the flexor tendons have been removed. Note the presence of only a single slip of *M. lumbricalis* and the strong development of *M. flexor hallucis brevis*. With digit IV directed caudally, *M. abductor digiti IV* acts more as an extensor of this digit than as an abductor.

fan-shaped belly extends distally, superficial to the tendons of *Mm. flexor digitorum longus* and *flexor hallucis longus*. As it reaches metatarsal I, the muscle gives rise to a broad, flat tendon that turns around the trochlea, crosses the metatarsal-phalangeal joint and inserts on the lateral surface of the base of the first phalanx. The insertion does not expand over the *flexor hallucis longus* tendon, as described in many birds.

A much smaller, distal head arises by tendinous fibers from the caudomedial surface of the tarsometatarsus about 3 mm from the proximal end of this bone. The flat belly extends parallel and superficial to that of the proximal head. The distal head inserts by fleshy fibers along the caudomedial surface of the proximal head, then gives rise to a short, flat tendon that fuses with the main tendon before crossing the metatarsal-phalangeal joint.

M. extensor hallucis longus (Figs. 14, 16: EHL).—This very small muscle consists of two parts. For reasons given in the Discussion, the homologies with *pars proximalis* and *pars distalis* are questionable. The larger, more proximal part arises from the medial surface of the tarsometatarsus just caudal (plantar) to the *M. tibialis cranialis* tuberosity and deep to the undivided tendon of *M. extensor digitorum longus*. The parallel-fibered belly follows the branch of this tendon to the base of the dorsal surface of the hallux. Here, it gives rise to two thread-like tendons. One inserts on the base of the proximal phalanx. The other extends distally alongside the *extensor digitorum longus* tendon and fuses with it on the distal end of the proximal phalanx.

There is an accessory extensor of the hallux consisting of only a few fibers. It arises from the medial surface of the tarsometatarsus about 3 mm distal to

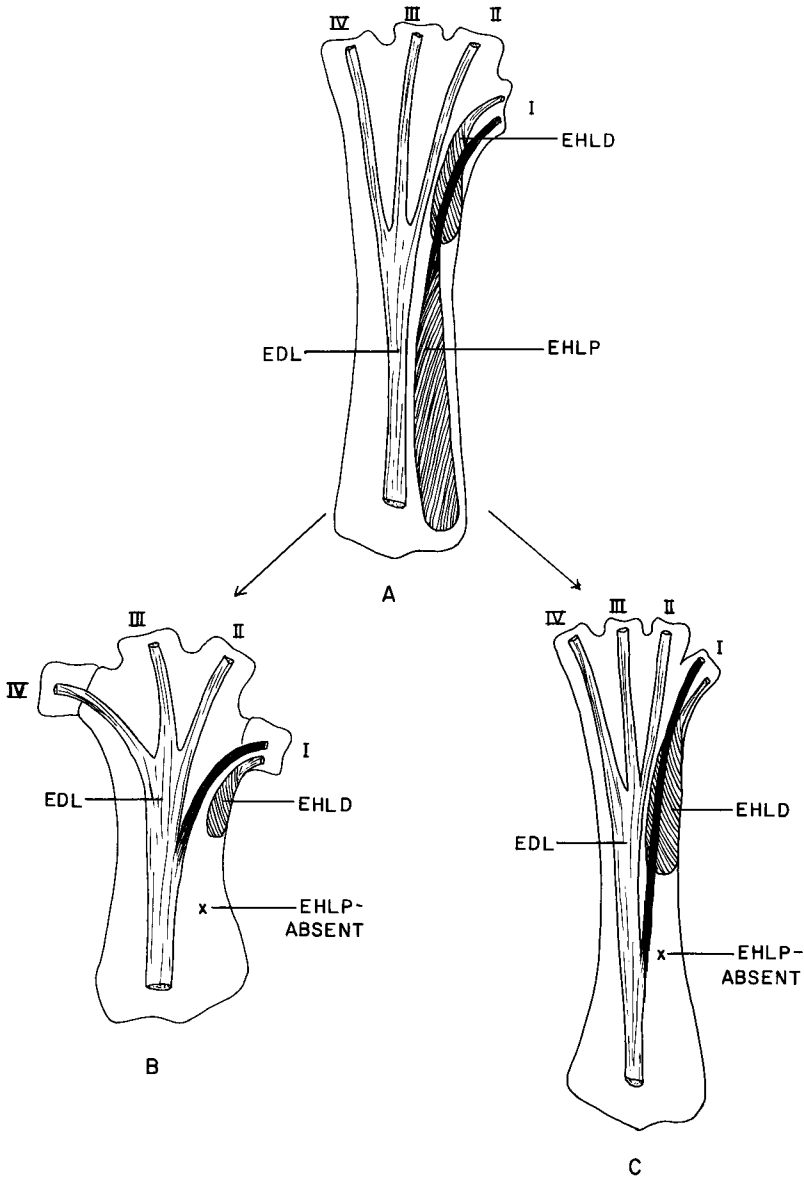


Fig. 16. Diagrammatic cranial view of the tarsometatarsus showing a possible scheme for the evolution of the unique branch of the extensor digitorum longus tendon to the hallux in the Psittaciformes and the Coliiformes. A. Hypothetical ancestral condition with branches only to digits II, III, and IV and both pars proximalis and pars distalis of *M. extensor hallucis longus* present. B. Psittaciform condition with branches to digits I, II, III, and IV. Pars proximalis of *M. extensor hallucis longus* is absent, and its tendon has presumably shifted to that of *M. extensor digitorum longus*. C. Coliiform condition with branches to digits I, II, III, and IV. Pars proximalis of *M. extensor hallucis longus* is also absent here, and a similar shift in its tendon to that of *M. extensor digitorum longus* is proposed. Note the strong development of *M. extensor hallucis longus* pars distalis as compared with that of the parrots dissected. Abbreviations given in Fig. 14.

the *M. tibialis cranialis* tuberosity. It extends along the cranial surface of the first metatarsal, passing through the retinacula with the tendons of its proximal counterpart and *M. extensor digitorum longus*. It inserts on the base of the proximal phalanx.

M. extensor proprius digiti III (Fig. 14: EPD3).—This is the most conspicuous of the cranial intrinsic foot muscles, lying just deep to the extensor digitorum longus tendons. It arises by fleshy fibers from the dorsomedial surface of the distal one-half of the tarsometatarsus and extends distally to cross the third metatarsal-phalangeal joint. It inserts as a broad aponeurosis across the entire dorsal surface of the base of the proximal phalanx.

There is a small muscle lying superficial to *M. extensor proprius digiti III*. It arises from the cranial surface of the tarsometatarsus for about 2 mm proximal to the origin of *M. extensor proprius digiti III*. The slender belly extends distally, over the medial edge of this muscle for about 7 mm. It then gives rise to a delicate tendon that crosses the medial surface of the metatarsal-phalangeal joint, extends along the dorsal surface of the proximal phalanx, and inserts on the base of the second phalanx. It is entirely independent from *M. extensor proprius digiti III*. This muscle has not been previously described in birds, and I have called it *M. extensor proprius digiti III accessorius* (EPD3A).

M. extensor brevis digiti IV (Fig. 14: EBD4).—This very small muscle originates from the cranial surface of the tarsometatarsus about 6 mm from its distal end. The belly is only about 1.5 mm long. It gives rise to a substantial tendon that passes around the lateral surface of the fourth metatarsal and inserts on the dorsolateral surface of the base of the proximal phalanx. It appears to function more as an adductor than an extensor.

M. abductor digiti IV (Fig. 15: ABD4).—This well-developed muscle arises from the deep lateral surface of the hypotarsus and from the caudolateral surface of the tarsometatarsus along a line from the lateral condyle to about 2 mm from the distal end of the fourth metatarsal. About two-thirds of the way down its length a tendon develops on its caudal margin. The tendon crosses the fourth metatarsal-phalangeal joint and inserts on the caudomedial surface of the base of the proximal phalanx. In an anisodactyl position this muscle would function as an abductor, but with the fourth digit directed caudally it acts as an extensor of the digit.

M. lumbricalis (Fig. 15: LM).—Only one rather poorly developed slip is present. It arises from the branches of the flexor digitorum longus tendon to digits II and III. It extends along the medial surface of the branch to digit III and inserts on the trochlea for this digit.

The following muscles are absent in *A. albifrons*: *M. ambiens*, *M. plantaris*, *M. popliteus*, *M. abductor*

digiti II, *M. adductor digiti II*, *M. extensor brevis digiti III*.

DISCUSSION

The thigh and shank.—The muscles of both the thigh and the shank of *A. albifrons* are relatively unspecialized. The few distinctive features that do occur are often variable from one specimen to another and have obscure functional significance.

In the thigh the absence of the postacetabular portion of *M. iliotibialis lateralis* and the separation of the two heads of *M. iliofibularis* may be useful in determining parrot relationships after comparative studies are carried out.

The two tendons of insertion of *M. tibialis cranialis* found in one of the six specimens is of uncertain significance. It is very probably an anomalous variation. Because this condition has been described only in *Bubo* and *Otis* (George and Berger 1966), however, it could have systematic implications if consistently found in other parrots.

The relative development of *Mm. fibularis brevis* and *fibularis longus* is quite variable among birds (George and Berger 1966). It is worth noting, however, that in *A. albifrons* *M. fibularis brevis* is by far the larger, and *M. fibularis longus* lacks the long tendon of insertion (Fig. 6).

Only the two flexors of digit II exhibit notable characters. The tendon of *M. flexor perforans et perforatus digiti II* is not perforated by that of *M. flexor digitorum longus*, a feature shared only with woodpeckers and a few others (George and Berger 1966). *M. flexor perforatus digiti II* lacks the femoral origin described for most birds.

The relationships of the flexor digitorum longus-flexor hallucis longus tendons are Type X of Gadow's (1893-1896) classification. This arrangement was illustrated, but not described, by Gadow in *Heliornis*. Gadow classified parrots as Type I, in which the tendon of *M. flexor hallucis longus* inserts on the hallux but is connected by a vinculum to the tendon of *M. flexor digitorum longus*. In Type X the two tendons are not connected by a vinculum. Instead, the flexor hallucis longus tendon divides into four branches, three of which fuse with those of the flexor digitorum longus tendon (Fig. 12). In the case of both types I and X, the hallux is acted

upon only by *M. flexor hallucis longus*, whereas the other three digits are flexed by both muscles.

The foot.—The most distinctive features of the hindlimb of *A. albifrons* are found in the pes, and it is very likely that they are related to the zygodactyl digit configuration or to its unusual manipulative ability. Most species of *Amazona* use their feet to at least some degree in grasping and handling food.

Flexion of the hallux is brought about by two muscles. *M. flexor hallucis longus*, in the shank, acts when flexion of the individual phalanges is required, but *M. flexor hallucis brevis*, an intrinsic foot muscle, causes flexion of the digit as a unit. Similarly, extension of the individual phalanges of the hallux is effected from the shank by *M. extensor digitorum longus*, whereas extension of the entire digit is brought about by an intrinsic foot muscle, *M. extensor hallucis longus*.

There are two possible explanations for the condition of the extensor hallucis longus (Fig. 16). It is likely that pars proximalis has been lost and that the large, distally located belly with the accessory insertion on the distal phalanx of the hallux is pars distalis. The very small, distal muscle would then be either a structure previously undescribed among birds or, more probably, the homologue of *M. extensor hallucis longus pars accessorius*, previously described only in the Coliiformes (Berman and Raikow 1982). The necessity for cranial rotation of the hallux in the mousebirds could account for the difference in position of this new muscle in the two orders. In parrots, both the accessory insertion of pars distalis and the presence of this "new" muscle could simply provide for more delicate control of the hallux. This explanation could also account for the branch of the extensor digitorum longus tendon to the hallux. This condition has been found in only one other avian order, the Coliiformes (Berman and Raikow 1982). In Coliiformes, because of the position of the muscle belly that is present, and its insertion, it is reasonably certain that *M. extensor hallucis longus pars proximalis* has been lost. Moreover, as in the parrots dissected, the branch of the extensor digitorum longus tendon to the hallux has a very proximal origin (Fig. 13), suggesting that it might have been captured from *M. extensor hallucis longus pars proximalis* when this muscle was lost. The selection pressure in Coliiformes was probably

toward more efficient operation of the digits in the zygodactyl configuration (Berman and Raikow 1982: 55). Parrots are permanently zygodactyl, and *Colius* occasionally uses this digit configuration. The extension of both caudally directed digits by the action of one muscle would be functionally advantageous over a system operating them separately, as occurs with the conventional anisodactyl configuration. This branch of the extensor digitorum longus tendon has not been found in the zygodactyl Piciformes (Swierczewski 1977) and Cuculiformes (George and Berger 1966), but neither of these groups uses the foot extensively in grasping or manipulating objects.

A second interpretation of *M. extensor hallucis longus* in *A. albifrons* is that the large belly is pars proximalis and its insertion on the distal hallux is thus as in other birds. The accessory structure would then be a much reduced pars distalis. Although this is the more conservative explanation, it raises problems. If the large belly of this muscle is pars proximalis, it has an unusually distal location on the tarsometatarsus, corresponding to the position of *M. extensor hallucis longus pars distalis* in those birds that have both parts. Also, with this interpretation, the branch of the extensor digitorum longus tendon to the hallux would have to be a new structure. Although this is no more unlikely than the appearance of a new muscle, there is no functional explanation for its very proximal origin from the main tendon. I presently favor the first explanation. It is to be hoped that future comparative dissections will allow additional insight.

There are two intrinsic foot muscles that supplement the action of *M. extensor digitorum longus* on digit III. *M. extensor proprius digiti III* is in a conventional position but very well-developed. *M. extensor proprius digiti III accessorius* (Fig. 14) has not been previously described in birds, and it seems likely that it produces a finer control over the digit. George and Berger (1966) describe a second extensor of this digit, *M. extensor brevis digiti III*. It originates from the extreme distal end of the tarsometatarsus and thus seems an unlikely homologue for the muscle described in this parrot.

Both intrinsic foot muscles affecting digit IV have undergone changes in their actions as a result of the caudal direction of this digit. *M. abductor digiti IV* (Fig. 15) functions more as an extensor than as an abductor here, whereas

M. extensor brevis digiti IV acts as an adductor (Fig. 14).

ACKNOWLEDGMENTS

I am grateful to Marion J. Mengel of the University of Kansas Museum of Natural History for providing the preserved specimens for dissection and to Robert J. Raikow for his invaluable constructive criticism of the manuscript. The manuscript was greatly improved by the suggestions of Richard Zusi, Gregory Bentz, and one anonymous reviewer. Thanks are also due to Doris Carrigan for typing the manuscript. This study was partially supported by a grant from the Charles and Rosanna Batchelor (Ford) Foundation, awarded to me by the Holy Cross College Committee on Professional Standards.

LITERATURE CITED

- BAUMEL, J. J., A. S. KING, A. M. LUCAS, J. E. BREAZILE, & H. E. EVANS (Eds.). 1979. *Nomina Anatomica Avium*. London, Academic Press.
- BENTZ, G. D. 1979. The appendicular myology and phylogenetic relationships of the Ploceidae and Estrildidae (Aves: Passeriformes). *Bull. Carnegie Mus. Nat. Hist.* No. 15: 1-25.
- BERMAN, S. L., & R. J. RAIKOW. 1982. The hindlimb musculature of the mousebirds (Coliiformes). *Auk* 99: 41-57.
- BOCK, W. J., & R. SHEAR. 1972. A staining method for gross dissection of vertebrate muscle. *Anat. Anz.* 130: 222-227.
- BORECKY, S. R. 1977. The appendicular myology and phylogenetic relationships of the avian "corvid assemblage." Unpublished Ph.D. dissertation. Pittsburgh, Pennsylvania, Univ. Pittsburgh.
- BRERETON, J. L. 1963. Evolution within the Psittaciformes. *Proc. 13th Intern. Ornithol. Congr.:* 499-517.
- CRACRAFT, J. 1981. Toward a phylogenetic classification of the Recent birds of the world (class Aves). *Auk* 98: 681-714.
- GADOW, H. 1893-1896. Muscular system. Pp. 602-620 in *A dictionary of birds*, part 3 (A. Newton, Ed.). London, Adam and Charles Black.
- GARROD, A. H. 1874. On some points in the anatomy of parrots which bear on the classification. *Proc. Zool. Soc. London* 1874: 586-598.
- GEORGE, J. C., & A. J. BERGER. 1966. *Avian myology*. New York, Academic Press.
- GLENNY, F. H. 1957. A revised classification of the Psittaciformes based on carotid artery arrangement patterns. *Ann. Zool. Agra.* 2: 47-56.
- HOLYOAK, D. T. 1973. Comments on taxonomy and relationships in the parrot subfamilies Nestorinae, Loriinae, and Platycercinae. *Emu* 73: 157-176.
- HOMBERGER, D. G. 1980. Funktionelle-morphologische Untersuchungen zur Radiation der Ernährungs-und Trinkmethoden der Papageien (Psittaci). *Bonner Zool. Monogr.* No. 13.
- MAURER, D. R., & R. J. RAIKOW. 1981. Appendicular myology, phylogeny, and classification of the avian order Coraciiformes (including Trogoniformes). *Ann. Carnegie Mus. Nat. Hist.* 50: 417-434.
- MIVART, G. 1895. On the hyoid bones of certain parrots. *Proc. Zool. Soc. London* 1895: 162-174.
- MUDGE, G. P. 1902. On the myology of the tongue of parrots, with a classification of the order, based upon the structure of the tongue. *Trans. Zool. Soc. London* 16: 211-278.
- RAIKOW, R. J. 1977. The origin and evolution of the Hawaiian honeycreepers (Drepanididae). *Living Bird* 15: 95-117.
- . 1978. Appendicular myology and relationships of the New World nine-primaryed oscines (Aves: Passeriformes). *Bull. Carnegie Mus. Nat. Hist.* 7: 1-43.
- , P. J. POLUMBO, & S. R. BORECKY. 1980. Appendicular myology and relationships of the shrikes (Aves: Passeriformes: Laniidae). *Ann. Carnegie Mus. Nat. Hist.* 49: 131-152.
- SALVADORI, T. 1891. *Catalogue of the Psittaci, or parrots, in the collection of the British Museum*. London, Longmans and Co.
- SIBLEY, C. G., & J. ALQUIST. 1972. A comparative study of the egg white proteins of non-passerine birds. *Bull. Peabody Mus. Nat. Hist.* 39: 159-168.
- SWIERCZEWSKI, E. V. 1977. The hindlimb myology and phylogenetic relationships in the avian order Piciformes. Unpublished Ph.D. dissertation. Pittsburgh, Pennsylvania, Univ. Pittsburgh.
- , & R. J. RAIKOW. 1981. Hind limb morphology, phylogeny, and classification of the Piciformes. *Auk* 98: 466-480.
- THOMSON, D. W. 1899. On characteristic points in the cranial osteology of the parrots. *Proc. Zool. Soc. London* 1899: 9-46.