

**Crown display of Golden-crowned Kinglet.**—On 2 November 1967 I handled, near Hillsborough, North Carolina, a female Golden-crowned Kinglet (*Regulus satrapa*) that did something I have not seen described. She several times partially erected the yellow crown feathers and broadened the patch by appropriate transverse separation of the feathers. The result, seen either from the front or the side was, not only to render the patch more conspicuous, but to make the head appear larger than normal. From above the black margins of the crown were almost concealed. I have seen no such reaction in four males of the species handled this year nor anything similar in many Ruby-crowned Kinglets (*Regulus calendula*) of both sexes.—CHARLES H. BLAKE, Hillsborough, North Carolina 27278.

**A Herring Gull chick (*Larus argentatus*) with an abnormal bill.**—Many records exist of abnormal bills in wild birds, but few of these refer to nonpasserine species. Pomeroy (1962) collected together much of the data on abnormal bills. Clarke (1967) reporting a case of a deformed lower mandible in a Slender-billed Gull (*Larus genei*) in Aden.

Few of the records that describe deformed or abnormal bills deal with the underlying bony structure of the bill but just describe the outward appearance of the bill. In one case, X-ray photographs of the deformed bills of a Scrub Jay (*Aphelocoma caerulescens*), a Red-breasted Sapsucker (*Sphyrapicus varius* (in part)), and a Californian Thrasher (*Toxostoma redivivum*) suggested that the underlying bony structure was normal (Fox, 1952).

On 4 August 1967 while banding Herring Gull chicks on Gull Island, Witless Bay,




Figure 1. Lateral, ventral, and dorsal views of the deformed bill of a Herring Gull chick.

Newfoundland, I found a chick with a grossly deformed bill, the only one I have noted in more than 1,500 chicks I handled (1,200 banded) in 1966 and 1967 (Figure 1). The chick had a wing length of 260 mm and weighed 651 g. "Normal" chicks with this wing length are much heavier (average wing length of 10 "normal" chicks 265 mm, SD 5.9 mm, range 256–276 mm; average weight 994 g, SD 85 g, range 797–1126 g). Thus the chick was patently having difficulty obtaining food and was probably slowly starving to death. The breast muscles were extremely small, forming only a very thin layer over the sternum, the keel of which was protruding. Many workers have found that birds with deformed bills are often heavily infested with ectoparasites (Kartman, 1949; Boyd, 1951; Ash, 1960; Worth, 1940). This chick was free of ectoparasites, even though many other chicks in the colony were heavily infested with both mallophaga and ticks.

As the rhamphotheca of this bird was obviously deformed it was decided to examine the underlying bony structure as well. Figure 2 shows the bony structure is manifestly deformed. The dentary and surangular of the right half of the lower mandible are turned outwards and downwards, while the left half is normal, the two halves of the lower jaw being equal in length. The left and right nasal bones and premaxillae are twisted to the right and downwards. The jugal bar on the right side of the skull is curved to the right, while the left bar is slightly concave near the quadrate and then curves to the right as it approaches the maxilla. The lacrymal bones are normal in shape, but do not bear the large backwardly-directed process seen in normal skulls. The portion of the nasal bone that runs down to meet the premaxilla is elongated on the right side of the culmen (20 mm) and short on the left side (10 mm). No connection exists between the premaxillary bone on the left side of the culmen and the bony palate (palatine, maxillo-palatine, and maxilla) on that side. The left palatine bone, which is not fused to the basisphenoid rostrum, is slightly shorter and broader than the right one and the maxillo-palatine bone in this region is not closely applied to the palatine as it is on the right side. The right maxillo-palatine is of normal shape, while the left one is shorter and more rounded than in a normal skull. The vomer is of normal shape and size but is twisted to the right. The quadrates and pterygoids are similar to each other and normal in size and shape.

The muscle scars on the parietal bones are smaller in the deformed skull than in a

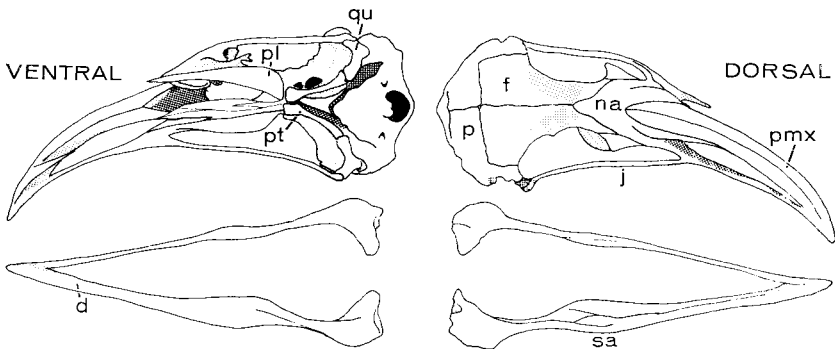


Figure 2. Dorsal and ventral views of the bony structure of the head of a Herring Gull chick with a grossly deformed bill. Key: d, dentary; f, frontal; j, jugal; na, nasal; p, parietal; pl, palatine; pmx, premaxillary; pt, pterygoid; qu, quadrate; sa, surangular.

normal skull, the scar on the left side being shallower than that on the right side, suggesting that the jaw muscles were better developed on the right side than on the left.

With its gross deformity and light weight it seems doubtful that the chick would have survived to maturity. No signs of damage or disease were noted in the dermotheca or bony part of the skull and it seems that the deformity may have resulted from a genetic change or an error in the development of the chick. As stated by Pomeroy (*op. cit.*) it could well be that passerines with abnormal bills adapt their behaviour more readily than many nonpasserines, and are thus more likely to survive and be recorded.

#### LITERATURE CITED

- ASH, J. S. 1960. A study of the Mallophaga of birds with particular reference to their ecology. *Ibis*, **102**: 93-110.
- BOYD, E. M. 1951. A survey of parasitisation of the Starling *Sturnus vulgaris* L. in North America. *J. Parasit.*, **37**: 56-85.
- CLARKE, G. 1967. Bird notes from Aden Colony. *Ibis*, **109**: 516-520.
- FOX, W. 1952. Behavioral and evolutionary significance of the abnormal growth of beaks of birds. *Condor*, **54**: 160-162.
- KARTMAN, L. 1949. Preliminary observations on the relation of nutrition to pediculosis of rats and chickens. *J. Parasit.*, **35**: 367-374.
- POMEROY, D. E. 1962. Birds with abnormal bills. *Brit. Birds*, **55**: 49-72.
- WORTH, C. B. 1940. A note on the dissemination of Mallophaga. *Bird-Banding*, **11**: 23-24.

WILLIAM THRELFALL, *Department of Biology, Memorial University of Newfoundland, St. John's, Newfoundland, Canada.*

**Weights of Black-billed Magpies from southwestern Montana.**<sup>1</sup>—Although Linsdale (*Pacific Coast Avif.*, no. 25, 1937) lists the weights of 28 Black-billed Magpies, *Pica pica hudsonia*, and reviews the literature on the development of nestlings, apparently no information has been recorded on the weights of magpies throughout the year or the weights of nestlings of known age. This paper presents the weights of three age classes of magpies collected over a 1-year period.

From April 1963 to April 1964, 145 Black-billed Magpies were collected within a 1-mile-square area in southwestern Montana, approximately 15 miles northwest of Bozeman, Gallatin County, for a parasitological survey (Todd and Worley, *J. Parasit.*, **53**: 364-367, 1967). The magpies were separated into the following age classes: nestlings (individually marked and of known age), first-year birds (fledglings to 1 year old), and adults (1 year or older). The plumage characteristics described by Linsdale (*op. cit.*) and the presence or absence of the bursa of Fabricius were used to determine the ages of adult and first-year birds.

We collected 10 adult or juvenile birds each month of the study period and 25 nestlings in May 1963. During April and May nests in the study area were examined daily, the dates of hatching were recorded, and the individuals were marked by toe clipping. The older birds were collected with a trap, except during March and June when some birds were shot. The trap was a cage of 1-inch-mesh wire 5 feet square and 3 feet high with a funnel-shaped entrance. It was baited with viscera from domestic livestock.

<sup>1</sup> Contribution from the Montana Veterinary Research Laboratory, Agricultural Experimental Station, Bozeman, Montana: Paper No. 852, Journal Series.