

us approached them slowly, until we were too close to use binoculars. One of the birds was adult, the other a bird of the year. As we watched, the young bird begged repeatedly, and the adult was seen to feed it at least twice, although the nature of the food could not be seen. In a species that nests as far north as does the Lapland Longspur it is certainly unusual for an adult to be still feeding a youngster at this late date, at this latitude. It is also unusual that this feeding activity was occurring in birds that had already molted into winter plumage.—SALLY F. HOYT, *Laboratory of Ornithology, Cornell University, Ithaca, New York.*

A Second Egg Tooth in a Mourning Dove?—A Mourning Dove *Zenaidura macroura*, hatched 6 June 1960, possessed a protuberance on the lower bill in a position and in color equivalent to the egg tooth on the upper bill. The size of the abnormal growth is perhaps twice that of the egg tooth. It also may be noted that the lower bill is slightly longer than normal in relation to the upper bill.

The photograph was taken after death at two days of age. The squab was being fed artificially, and its death was not necessarily related to the abnormality.

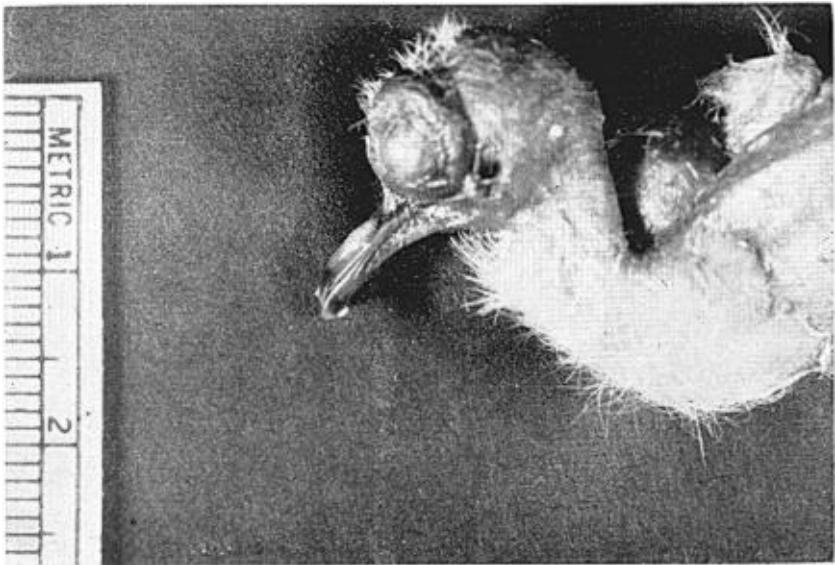


Figure 1. Abnormal growth resembling egg tooth on lower bill of a young Mourning Dove.

A "cold shock" was possible midway through incubation when both parents were frightened by children and left the nest for several hours. The parents were not siblings, otherwise their relationship is unknown.—WILMER J. MILLER, *Department of Microbiology, Serology Laboratory, School of Veterinary Medicine, University of California, Davis, California.*

An Old New York Record for the White Pelican.—On Thursday, 11 December 1788 *The New York Journal and Weekly Register* (p. 2) carried the following item: "A few days ago, a curious and uncommon BIRD was killed at Saratoga and sent, as a rarity, to Albany. The distance from the tip of one wing to the