

long and averaging 0.09 inches thick. They were moderately active when removed from the larval cases.

A number of larvae and some infested stalks were taken to the American Museum of Natural History and given to Dr. James McDunnough, an authority on the Lepidoptera, who placed them where they could transform. Unfortunately, nothing hatched but parasites. In a subsequent letter, Dr. McDunnough said it was quite safe to call the species *Epiblema strenuana* Walker, a tortricid moth that is a well-known borer in Ambrosia.

I am indebted to Mr. W. L. McAtee for reviewing the manuscript and suggesting ways to improve it.—RICHARD B. FISCHER, *Cornell University, Ithaca, New York.*

**Surgery for Sexing and Observing Gonad Condition in Birds.**—In many species of birds there are no suitable criteria by which the sex of individuals can be determined except by direct examination of the gonads. Even where there are differences in plumage, wing length, body weight, or coloration of bill and feet, sexing is often only a little better than guessing because of the overlap in these characters. In addition, many of the criteria useful during the breeding season (e. g., the incubation patch, song, nuptial plumage, and sexual behavior), are useless at other times of the year.

In field and laboratory studies it may be advantageous to know promptly and accurately the sex of individuals or to know precisely the condition of the ovary or testes. The latter is especially true in studies of photoperiodicity. The purpose of this paper is to describe in detail the surgical procedure used in sexing birds, to point out ways in which the operation will be useful in field and laboratory studies, and to indicate from my own results the degree of success that can be expected. This work was supported by a fellowship from the Bank of America-Giannini Foundation.

The operation consists of making a small incision on the left side between the last two ribs, thus permitting a satisfactory view of the ovary or left testis. The procedure varies somewhat according to the size and structure of the species concerned and according to the conditions under which the operation is performed. There are many advantages to be gained by bringing the birds into the laboratory, but satisfactory results can be had in the field. Elaborate sterility precautions are not necessary, but all instruments and materials should be scrupulously clean. When the operation is performed in the field it is best to maintain a special kit which can be kept separate from dissecting and skinning equipment.

Ether or intramuscular injections of a barbiturate can be used as an anesthetic. A barbiturate is preferred for smaller birds since ether causes excessive formation and accumulation of mucus in the respiratory tract. The birds should be anesthetized so that they will remain so for about 10 minutes; thus, the correct dosage of the anesthetic must be determined for each species. Sixty milligrams per kilogram of body weight is an approximate formula from which to work. With smaller birds I use a 2 per cent solution of Nembutal dissolved in 10 per cent ethanol, and inject in the following dosages: Oregon Junco (*Junco oreganus*) and Song Sparrow (*Melospiza melodia*), 0.05 ml.; White-crowned Sparrow (*Zonotrichia leucophrys*), 0.07 ml.; Brown Towhee (*Pipilo fuscus*) and Robin (*Turdus migratorius*), 0.10 ml.; and domestic pigeon (*Columba livia*), 1.5 ml. The Nembutal is injected into the breast muscle, and the operation is started as soon as the bird is anesthetized. Intra-peritoneal injections are to be avoided because of complications with the air-sacs. If the operation has not been completed by the time the bird revives, a second injection consisting of one-half of the original dosage should be administered.

Birds of robin-size, or larger, should be tied to a board with the left side up and with the left leg extended and retracted with a band of cloth. Smaller birds can also be treated in this fashion, but I prefer to hold them in the left hand with the head and left wing under the thumb and the left leg retracted with the first and second fingers (figure 1). Except on birds heavily clothed with feathers, the outline of the lung (orange or pinkish), the ribs, the kidney, and other abdominal viscera can be seen. The feathers overlying the posterior end of the lung, the kidney, the thigh, and the last few ribs may be plucked. If left on, they will get in the way of the operation, especially when the incision is being sutured.

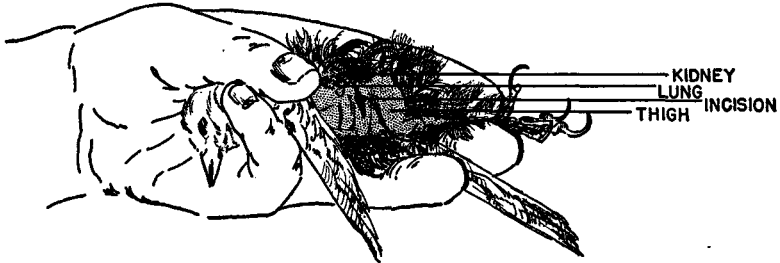


Figure 1. Manner in which small birds are held for surgery, area to be plucked, and site of incision for examining the gonads.

With the thigh retracted posteriorly, an incision is made through the skin and body wall between the last two ribs. The incision should be about 2 centimeters long in pigeons and about 0.5 to 1 centimeter in the Oregon Junco. In larger birds the skin should be cut first in order to locate accurately the position of the ribs, but in smaller birds the skin and the body wall can be cut at the same time with a pair of small, sharp-pointed scissors. The incision should be started ventrally and then carried dorsally between the ribs to near the posterior end of the lung (figure 1). The incision is actually made into the abdominal air-sacs, thus there is little danger of injuring the viscera. Great care must be taken, however, not to cut or injure the kidneys or lungs by extending the incision too far dorsally.

The incision can now be spread gently with a pair of blunt forceps. Small swabs (a bit of cotton rolled on a toothpick) should be handy for wiping up small drops of blood and for manipulating the viscera. A small wire retractor is useful for spreading the incision when working with small birds held in the hand. The beam of a dissecting lamp or flashlight mounted on a stand is directed into the body cavity while the gonads are being examined, and even measured with calipers, if desired.

In large birds, and with small ones released again in field studies, the body wall should be closed with two or more single sutures (light silk thread). The sutures should go around the ribs; the body wall is then pulled together tightly. The skin can be closed with several single sutures or by a continuous stitch. In water birds the incision should be painted with a 6 per cent celloidin solution. A single suture closing both the body wall and the skin is satisfactory for small birds which will be kept in captivity. Birds that are to be released should be placed in small cages overnight, or for at least four hours, after which the sutures should be rechecked. It is also advisable at this time to apply more celloidin to water birds.

Several hundred birds have been examined surgically in my studies during the last year with less than one per cent mortality. In nearly every case death was due to too much anesthetic, but occasionally the kidney was injured with the point of the

scissors; the resulting hemorrhage caused congestion of the respiratory tract via the air-sacs. Many birds were operated on weekly or biweekly for three to eight weeks without any ill effects. In such cases the incision was made on the old line, and healing was as prompt in the later operations as in the first. For the most part, these birds were kept in light chambers for photoperiodicity studies, and the operation seemed to have no effect on their ability to respond to day length increments since their response was similar to that of unoperated birds. Occasional weighing of the birds showed that the operation caused no loss of body weight, and in all respects they appeared to be normal and healthy.

In field studies 27 individuals of 5 species, ranging in size from Oregon Juncos to Brown Towhees, were examined surgically, color banded, and released for observation. These birds were watched for a period of several months, and at the end of this time only three could not be found and had presumably died. Two pairs of White-crowned Sparrows have been alive for over a year since operation and have also raised successful broods since then. The use of surgery for sexing birds in studies of nesting behavior, for determining sexual difference in call notes and song, etc., should be of great benefit. Gordon W. Gullion, in his study of sexual behavior and call notes of the American Coot (*Fulica americana*) (unpubl. M. A. thesis, Univ. of Calif., Berkeley, 1950), used the procedure outlined here with considerable success. He used ether as an anesthetic and the percentage of survival was high.—ROBERT E. BAILEY, *Division of Anatomy and Institute of Experimental Biology, University of California, Berkeley, California, March 13, 1952.*

**Additional Notes on the Birds of Bimini, Bahamas.**—The recent report on the birds of Bimini by Charles Vaurie (1953, *Auk*, 70: 38–48) deals with the summer birds (June–August). A visit in the spring (March 28 to April 18, 1952) has enabled me to make some interesting comparisons.

#### BREEDING BIRDS

Only few of the breeding birds seem to be permanent residents. Among the latter are the ground dove (*Columbigallina passerina*), the mocking bird (*Mimus polyglottos*), the Bahaman Woodstar (*Calliphlox evelynae*), the grassquit (*Tiaris bicolor*), the Thick-billed Vireo (*Vireo crassirostris*), and the sugarbird (*Coereba flaveola*). Others observed by Vaurie were either not observed at all or only as obvious spring arrivals.

Green Heron (*Butorides virescens*)—During many trips through the mangrove creeks, only a single bird was seen (April 11).

Yellow-crowned Night Heron (*Nyctanassa violacea*)—Not observed.

Clapper Rail (*Rallus longirostris*)—Not once heard.

Bridled Tern (*Sterna anaethetus*), Sooty Tern (*Sterna fuscata*), Least Tern (*Sterna albifrons*), and Common Noddy (*Anous stolidus*).—All four species were absent from their breeding colonies, as well as from the waters around Bimini.

White-crowned Pigeon (*Columba leucocephala*)—Not observed during many visits to their favorite habitats.

Mourning and Zenaida doves (*Zenaida macroura* and *aurita*)—Not observed.

Nighthawk (*Chordeiles minor*)—All calling nighthawks had the call of North American birds. There was no evidence that the native birds had yet arrived.

Gray Kingbird (*Tyrannus dominicensis*)—First seen April 8 (1), recorded also April 9 (1), April 14 (2), April 16 (1). All these birds were completely silent and were either passage migrants on the way to Florida and the Carolinas or recently arrived residents.