

ON THE LOCOMOTOR ANATOMY OF THE BLUE COUA,
COUA CAERULEA

BY ANDREW J. BERGER

THIS is the third in a series of papers on the anatomy of the Cuculidae. The anatomy of at least a third of the genera of cuckoos apparently has never been investigated. Of most of the remaining genera, data have been published on only a few anatomical characters. Beddard (1898: 280-281) and Pycraft (1903: 287) classified the cuckoos whose anatomy was known to them (less than half of the genera). Both authors used leg-muscle formulae and structure of the syrinx. Beddard also used certain features of the pterylosis, whereas Pycraft adopted osteological features in his system. The two systems resulted in considerable disagreement as to the placement and relationship of genera. Garrod and his successors determined the leg-muscle formula in all genera available to them; Beddard (*op. cit.*, p. 280) gave the formula of *Coua* as ABXYAm. Except for the following three papers, however, nothing has been published on the detailed anatomy of the lower extremity of cuckoos: Shufeldt, 1886, on *Geococcyx californianus*; Hudson, 1937, *Coccyzus americanus*; Berger, 1952, *Coccyzus erythrophthalmus*, *Crotophaga sulcirostris*, and *Geococcyx californianus*. Garrod (1881: 360), Fürbringer (1888, Plate 23), Gadow (1891: 256), Beddard (*op. cit.*), and Lowe (1943) mentioned or illustrated the structure of the tendon of *M. tensor patagii brevis* in cuckoos, but the total wing myology has not heretofore been described. I recently described the pterylosis of *Coua caerulea* (Berger, 1953).

All attempts to classify the Cuculidae have been unsatisfactory, and I have found it impossible to classify them by compiling data supplied with the several systems proposed. It is obvious that reclassification can be accomplished only after the anatomy, behavior, and ecology of each genus have been studied. This paper is a contribution toward that end.

I am indebted to the following who have made this study possible: Dr. Jacques Berlioz, Muséum National d'Histoire Naturelle, Paris, and Dr. Dean Amadon and Mr. Charles E. O'Brien, American Museum of Natural History, who sent me alcoholic specimens of *Coua caerulea*; Mr. E. Banks, British Museum (Natural History), London, and Dr. Herbert Friedmann, United States National Museum, for the loan of skeletal material.

OSTEOLOGY

Milne-Edwards and Grandidier (1878) illustrated articulated skeletons of *Coua pyropyga* (= *C. cristata pyropyga*), *caerulea*, *gigas*, *ruficeps olivaceiceps*, and *coquerebi*, as well as certain disarticulated bones of *C. serriana*, *caerulea*, *cristata*, *ruficeps olivaceiceps*, and *gigas*, and (1879) presented a series of measurements of bones of several species. Pycraft (1903) illustrated the skull, sternum, and shoulder girdle of *C. reynaudii*.

Even at the present time, one cannot attempt a thorough analysis of this genus because of the lack of material. In view of their obvious historical value, the specimens studied by Milne-Edwards cannot be obtained on loan. By writing to numerous museums, both in the United States and abroad, I have been able to secure four skeletons of the genus *Coua*: two complete skeletons of *caerulea*, and one body skeleton each of *cristata* and *reynaudii*. The following discussion, therefore, deals with this material. Measurements were made with dial-type calipers, accurate to one tenth of a millimeter.

Each of the three species has 14 cervical vertebrae, of which the last two possess cervicodorsal ribs. The last cervicodorsal rib bears an uncinat process. The atlas is perforated by the odontoid process (see Beddard, 1898: 117 and 280).

There are four free dorsal vertebrae, each of which bears a vertebral rib which articulates with the sternum by means of a sternal counterpart. Each of the first three dorsal ribs bears an uncinat process, but this structure is wanting on the last dorsal rib. I was unable to find any evidence of a thoracic rib either in *C. caerulea* or *C. reynaudii*. Whether this lack represents a species character or is due to inadequate material I cannot say. The fact is that one disarticulated thoracic rib was found with the skeleton of *C. cristata* and two facets for this rib are present on each side of the first fused vertebra of the synsacrum. This rib has both a vertebral and a sternal portion, but I am confident that the latter attached to the sternal portion of the last dorsal rib, rather than to the sternum directly. I found a similar condition in *Coccyzus americanus* and *C. erythrophthalmus*. Pycraft (1903: 274) said of the Cuculidae: "The sternal segments of the fifth pair of thoracic ribs never reach the sternum. They may persist as vestiges, even the thoracic segment of the rib reaching the verge of disappearance, as in *Coua* [*reynaudii* and *caerulea*?] and *Rhamphococcyx*." Milne-Edwards and Grandidier (*op. cit.*) said that there are six ribs in the genus *Coua*: the anterior two are cervicodorsal ribs, the posterior four are true, or dorsal, ribs. They said nothing about the presence of thoracic ribs. Yet in their Plate 59, an articulated skeleton of *C.*

coquereli, they have illustrated *eight* ribs, of which the first three are cervicodorsal ribs. Although uncommon, such variation is to be expected in the number of these ribs. The eighth rib, mentioned above, might be a thoracic rib, but one cannot tell certainly from the illustration.

Pycraft further stated (*op. cit.*, p. 273): "The most complete synsacrum is that of *Coua*, and is made up as follows:—1 thoracic, 3 lumbar, 3 lumbo-sacral, 2 sacral, and 4 caudal, making 13 in all." By using intervertebral foramina and transverse processes, I have been able to count only 11 fused vertebrae in the synsacra of the two specimens of *C. caerulea* from the British Museum. One of these skeletons was studied by some earlier ornithologist, who marked in ink transverse lines on the synsacrum to indicate the approximate fusion planes of the vertebrae: the total number of fused vertebrae thus indicated is 13. I counted 13 fused vertebrae in the synsacra of *reynaudii* and *cristata*.

Three specimens of *caerulea* have, respectively, four, five, and six free caudal vertebrae, while a fourth specimen (alcoholic) has five with a sixth partially fused with the pygostyle. The free caudal series is not complete in the specimens of *cristata* and *reynaudii*. Pycraft (*loc. cit.*) said: "There are 6 or 7 post-synsacrals—free caudal vertebrae," in the Cuculidae. Milne-Edwards and Grandidier (1879: 170) reported that generally there are seven free caudal vertebrae in *Coua*, but recognized that there might be less than seven, due to fusion with the pygostyle. (See Berger, 1952: 520, regarding variation in number of free caudal vertebrae.)

TABLE I

Species	Length of Sternum	Maximum Width of Sternum	Ratio	Length of Carina	Height of Sternum ¹	Ratio	Locomotor Habits
<i>reynaudii</i>	27.5 mm	19.8	1: .72	26.3	8.7	1: .33	Terrestrial
<i>cristata</i>	35.3	31.0	1: .88	35.1	12.4	1: .35	Arboreal
<i>caerulea</i> ²	32.9	29.7	1: .90	32.2	11.6	1: .36	Arboreal

¹ Overall height of sternum at anterior border of carina.

² Averages of two specimens.

The two pygostyles of *caerulea* measured in total height and width at the base, 17.0, 5.4, and 17.6, 5.7 mm., respectively. A disc is present, therefore, although relatively it is slightly less developed than in *Coccyzus erythrophthalmus* or *C. americanus* (see Berger, 1952: 521).

The sternum is double-notched in each of the three species studied (see Fig. 2), although one alcoholic specimen of *caerulea* and the skeleton of *reynaudii* exhibit a partial obliteration by ossification of the notch between the external lateral and the internal lateral xiphoid processes. There is considerable difference in development of the

sternum, but this is not shown clearly in measurements of the carina itself. The best mensural indicators of overall sternal development seem to be total length of sternum and maximum width at the external lateral xiphoid processes.

The averages of measurements (in millimeters) of bones of two specimens of *C. caerulea* follow: length of dorsal region, 33.1; humerus, 44.5; ulna, 38.6; radius, 34.9; carpometacarpus, 18.9; digit II, 17.3; femur, 50.3; tibiotarsus, 85.4; tarsometatarsus, 55.2; hallux, 23.1; digit II, 31.7; digit III, 46.8; digit IV, 40.7; cranium (nasofrontal hinge to occiput), 35.4; interorbital width, 10.6; interparietal width (greatest), 26.8; length of synsacrum, 39.2; greatest width of pelvis (at posterior iliac crest), 35.1; width at pectineal processes, 26.3; width at anterior iliac processes, 23.0; length of pectineal process, 6.5; length of scapula, 38.3; length of coracoid, 26.8; length of furculum, 28.0.

The total length of the bony wing (119.3 mm.) is 50.2 per cent the length of the leg (237.7, including digit III). This ratio is less than that found in *Crotophaga sulcirostris* (59%) and approximately the same as that in *Geococcyx californianus* (49%) as given by Berger (1952: 526). If we exclude digit III from total leg-length, then the ratios of wing-length to leg-length in *Coccyzus erythrophthalmus*, *Crotophaga sulcirostris*, *Coua caerulea*, and *Geococcyx californianus*, become, respectively, 93.9, 74.3, 62.5, and 59.8%.

From the above data, one might conclude that *Geococcyx californianus* and *Coua caerulea* must have nearly the same locomotor habits. Further analysis, however, reveals that a simple wing-length/leg-length ratio is inadequate for an understanding of the locomotor pattern in these two birds. Using length of the dorsal region as a standard, I computed ratios between this complex and the several elements composing the wing and leg. In order to make comparisons between *Coua* and other genera of cuckoos, I further computed the increase or decrease in length of limb elements of *Coua caerulea* by using the same elements of *Coccyzus erythrophthalmus* as standard. Table II presents the results.

TABLE II
CHANGES IN LIMB ELEMENTS BASED ON *COCCYZUS ERYTHROPTHALMUS*

Element	<i>Crotophaga sulcirostris</i>	<i>Coua caerulea</i>	<i>Geococcyx californianus</i>
Humerus	- 6.1%	- 8.0	+ 1.3
Ulna	-17.1	-16.9	-10.0
Manus ¹	-12.9	-25.6	-17.6
Femur	+ 1.4	+ 9.9	+28.2
Tibiotarsus	+15.0	+33.5	+44.5
Tarsometatarsus	+14.6	+28.5	+58.4
Digit III	+ 2.4	+13.5	+16.0

¹ carpometacarpus plus digit II

Several points are obvious from these data. There is a progressive decrease in each element of the wing of *Coua* from those bones in *Coccyzus*, a migratory genus. The wing of *Coua* appears to show a greater decrease than does that of *Geococcyx*. Each element of the leg of *Coua* shows an increase over those elements in *Coccyzus*, but the increase is not progressive distad. One finds in general, then, a bird whose wing is considerably shortened from that of an arboreal migratory bird, and whose leg is considerably lengthened, even though the increase in the several segments does not follow what might be termed the "classical pattern" for concomitant changes in fore- and hindlimbs as correlated with locomotor habits. As a consequence, one might expect *Coua caerulea* to be a cursorial bird which uses its wings but little. It is, however, arboreal in habits. Sibree (1891: 218-219) reported that: "Five species of *Coua* [one of which is *caerulea*] inhabit the large forests, or at least the wooded regions, where they are found jumping from branch to branch in search of their food, which consists of insects, and especially of land-mollusks These five species are true climbers The climbing Couas go from tree to tree, cocking their tails, and making the solitudes of the forest resound with their short sharp cry."

Rand (1936: 223) also considered *Coua caerulea* "an arboreal bird of the humid forest," and (p. 401) stated: "The blue coua ranges through the forest from the tree tops through the middle spaces into the undergrowth, sometimes even running on the ground, and also ranges through the larger secondary brush." I wrote to Dr. Rand asking for further information on the way in which these birds move about through the trees. From his answer, I quote the following: "The three arboreal species *caerulea*, *cristata*, and *verreauxi* are geographical replacements. The terrestrial rain-forest species, *reynaudii* and *serriana*, have different food, one insects, one fallen fruit. In the dry forests and brush are four species, one rather wide-spread (*ruficeps*), but the other three are more restricted. *C. coquereli* and *cursor* are geographical representatives, and the much larger *C. gigas* co-exists with *C. coquereli* but overlaps the range of *C. cursor*.

"The group is, to my mind, a terrestrial type. The terrestrial species are at home, agile and graceful on the ground, swift on foot, and may prefer to escape danger on foot rather than flying or seeking concealment. The arboreal species, and this includes *C. caerulea*, have carried over as much of this as possible into their arboreal life. *C. caerulea* definitely does not climb about like a parrot.

"The various modifications in range, habitat, and habits seem to be the result of an intra-group pressure and competition with little

competition, in island isolation, from other groups. They have modified these without modification in structure.

"Thus, to use *Coua caerulea* as an example of an arboreal cuckoo is a mistake. It is a terrestrial-type that has taken to living in trees! Hence, its resemblance in leg-proportions to *Geococcyx* is what I would expect."

It is interesting to note in this connection that Milne-Edwards and Grandidier (1879: 170) commented on differences in development of the leg in various species of *Coua*. The following is a free translation of a portion of their comments: One does not perceive any relation between the habits of the birds and the dimensions of the tarsus; thus, the tarsi are long in *Coua caerulea*, which is arboreal, and in *Coua gigas* and *ruficeps*, which are terrestrial; they are, on the contrary, short in *Coua reynaudii* and in *Coua cursor*, whose habits are very different, the first being a climber and the second a runner.

The results obtained here point up sharply the difficulties and dangers involved in analysis of inadequate material and the necessity for considering ecological factors in the interpretation of anatomical data. It is unfortunate that it is not possible to present a thorough analysis of each species of the genus *Coua*, since it does contain both arboreal and terrestrial species. Before one can comment with much assurance on the significance of limb proportions, for example, between *Coua* and any other genus, he must know how much variation occurs within the genus *Coua* itself. This seems especially necessary because the relationship of *Coua* to other genera of cuckoos is at best imperfectly known.

MYOLOGY OF THE APPENDAGES

Because the appendicular myology of the genus *Coua* has never been described, I have included certain details which should prove useful in further study directed to reveal adaptive changes in arboreal and terrestrial species within the genus and to reveal intergeneric relationships. Even though a living muscle continually changes in dimensions, the area of origin, of course, remains constant in a given specimen. The relative degree of development of a fleshy belly can be determined in alcoholic material and is useful in functional anatomical studies as well as for determining relationships. Features which, in a sense, may be more directly applicable to systematics are the presence or absence of a muscle or any peculiarity in its structure or relationship.

Terminology for wing muscles unless otherwise indicated follows Fisher (1946), who adopted names used by Howell (1937), Gadow

(1891), and Shufeldt (1890). For the sake of uniformity, I have used the same names for leg muscles as in my earlier paper (Berger, 1952). Osteological terminology follows Howard (1929). All dissection was done with the aid of a binocular microscope using ten times magnification.

A study of the nervous system of cuckoos has been started, but a report is premature. Consequently, I have said nothing about innervation. A thorough study of the innervation of wing muscles, for example, involves not only investigation of terminal nerve branches and the gross pattern of the brachial plexus, but also the localization within the central nervous system of the nerve cell bodies whose neuraxones form the brachial plexus and its terminal branches. Such an investigation, in turn, implies that one conduct neurone chromatolysis experiments. Although this type of anatomical study should be made, I do not believe that, for purposes of classification, the results to be obtained by this approach warrant, at present, the amount of labor involved.

DESCRIPTION OF WING MUSCLES

M. PECTORALIS SUPERFICIALIS (fig. 1)

This large single muscle covers *Mm. supracoracoideus*, *coracobrachialis posterior*, *sternocoracoideus*, and *coracobrachialis anterior*. It arises from the ventral one-third of the anterior two-thirds of the carina; the anterolateral and all of the posterior half of the body of the sternum; the internal lateral and external lateral xiphoid processes (Coues, 1903: 150) and the interxiphoid membranes; the costosternal membrane; and from the anterior and lateral aspects of the furculum and the adjacent surface of the coracoclavicular membrane throughout nearly their entire length. The belly extends dorsolaterad to the upper margin of the horizontal portion of the sternal ribs. It inserts on a triangular area on the palmar surface of the deltoid crest (pectoral crest, Shufeldt, 1890: 70). The insertion is mostly fleshy but it is surrounded by a dense fascial envelope. A fleshy fasciculus ("M. pectoralis, pars propatagialis" of Gadow) splits off from the superficial surface of the belly near its insertion. From this fasciculus, tendinous bands pass to the belly of *M. tensor patagii brevis* and to the tendon of *M. tensor patagii longus*.

M. SUPRACORACOIDEUS (fig. 2)

Laterally, the belly of this muscle is in contact with *M. coracobrachialis posterior*, and, superficially, both muscles are covered by *M. pectoralis superficialis*. *M. supracoracoideus* arises fleshy from about the dorsal two-thirds of the carina in its anterior two-thirds; from a triangular area on the anteromesial aspect of the body of the sternum adjacent to the carina; from the basal half of the anterior and medial surfaces of the coracoid; and from the basal two-thirds of the coracoclavicular membrane. There is no origin from the furculum. Fleshy fibers cover the tendon to within 3 mm. of the insertion. The tendon forms on the deep coracoidal aspect of the belly, and passes anterodorsolaterad through the triosseal canal to insert on the anterior edge of the humerus at the junction of the articular head and the deltoid crest. The tendon is concealed in a palmar view by *M. coracobrachialis anterior*.

M. CORACOBRACHIALIS POSTERIOR (fig. 2)

This muscle arises mostly fleshy from the sternocoracoidal process of the coracoid, from the lateral and posterior surfaces of the basal 12 mm. of the coracoid, and semitendinous from the anterolateral edge of the body of the sternum. It inserts by a short, stout tendon on the apex of the internal tuberosity of the humerus.

M. LATISSIMUS DORSI (figs. 3, 4)

This is the most superficial muscle complex on the dorsum and is, in reality, two muscles plus a dermal component.

1. *Pars anticus*. This anterior, thin, sheet-like portion arises by an aponeurosis attached to the neural spines of the last two cervical (13 and 14) and the first two dorsal vertebrae, though it attaches only to the anterior tip of the spine of dorsal vertebra 2. The area of origin is about 14 mm. long. The belly passes outward and forward, and between the scapulothoriceps and humerotriceps, to insert on the anconal surface of the humerus, beginning about 12 mm. distal to the head, by a short (1 mm.), broad (5 mm.) tendinous band.

2. *Pars posticus*, likewise sheet-like in form, arises by an aponeurosis attached to the neural spines of dorsal vertebrae 2 and 3, and to the tendons of *M. longissimus dorsi* in the region of dorsal vertebra 4. The muscle is about 14 mm. in width at its origin. Just before entering the arm musculature, the belly passes deep to *pars anticus* and tapers to a flat tendon (6 mm. long and 1 mm. wide), which passes diagonally upward to its insertion on the humerus about 1 mm. proximal to the area of insertion of *pars anticus*.

3. *Dermal component*. This is a fleshy strap 7 mm. wide at its origin from the superficial surface of *pars posticus* in the region of dorsal vertebrae 2 and 3. The midportion of the belly is 2 mm. wide, but it broadens out to about 4 mm. at its insertion into the skin at the posterior margin of the humeral feather tract, slightly anteromesial to the insertion of the dermal component of *M. serratus posterior*.

M. RHOMBOIDEUS SUPERFICIALIS (figs. 3, 4)

The posterior portion of this muscle lies deep to *M. latissimus dorsi, pars anticus*, but the anterior part lies immediately deep to skin and superficial fascia. Posteriorly, the belly overlies the anterior half of the deeper *M. rhomboideus profundus*. The origin is by an aponeurosis from the neural spines of the last three (12, 13 and 14) cervical and the first two dorsal vertebrae, that from dorsal vertebra 2 being from the anterior tip of the spine only. The area of origin is about 25 mm. in length. It inserts by fleshy fibers on the dorsomesial surface of the scapula, beginning on the acromion process and extending caudad 26 mm.

M. RHOMBOIDEUS PROFUNDUS (fig. 4)

This muscle arises by an aponeurosis from the neural spines of the last two cervical, and by fleshy fibers from the first two dorsal vertebrae. The muscle is overlapped in its anterior half by *M. rhomboideus superficialis*. Whereas the fibers of *M. rhomboideus superficialis* pass forward and outward, those of *profundus* pass backward and outward to insert fleshy on the caudal 14 mm. of the dorsomedial surface of the scapula.

M. CORACOBRACHIALIS ANTERIOR (figs. 2, 4)

This fleshy muscle is 15 mm. in length and 2.5 mm. wide at its origin from the head of the coracoid, the coracohumeral ligament, and the tendon of origin of *M. biceps brachii*; it is 8 mm. wide at its insertion on the palmar surface of the humerus just proximal to the area of insertion of *M. pectoralis superficialis*. The belly covers

the anterior edge of the head of the humerus and the tendon of insertion of *M. supracoracoideus*. Posteriorly, the belly is overlapped by the tendon of origin of *M. biceps brachii*.

M. TENSOR PATAGII BREVIS (figs. 1, 3)

This is a strap-shaped fleshy muscle arising from the medial surface of the furculum and the acromion process of the scapula. The belly is about 25 mm. long and 7 mm. at its maximum width. It is inseparably fused with *M. tensor patagii longus*. Two tendons arise from the distal end of the fleshy belly. The one tendon represents that of *M. tensor patagii longus*, the other that of *M. tensor patagii brevis*. The latter is a narrow band about 2 mm. wide, which passes distad parallel to the humerus. Distally the tendon bifurcates. The short branch inserts into the heavy fascia covering the superficial surface of *M. extensor metacarpi radialis*. The long branch fuses with the antibrachial fascia, which extends the entire length of the forearm, covering the muscles and attaching to the bases of the greater secondary coverts. The strong tendinous band from the superficial fasciculus of *M. pectoralis superficialis* inserts into the belly of *M. tensor patagii brevis* just before the formation of its tendon.

M. TENSOR PATAGII LONGUS (figs. 1, 3).

One cannot separate the belly of this muscle from that of *M. tensor patagii brevis*. The fibro-elastic tendon (2 mm. wide proximally) of the longus passes distad in the anterior edge of the proptagium and becomes tendinous near the distal end of the forearm. A thin tendon arising from the superficial fasciculus of *M. pectoralis superficialis* joins the fibro-elastic portion of the tendon at its formation. There is a minor insertion on the extensor process of metacarpal I, but the tendon fans out to cover the pollex and to attach to the bases of the alula quills, and, on the palmar surface of the manus, it fuses with the deep fascia.

M. DELTOIDEUS MAJOR (figs. 1, 3)

This bulky muscle has two heads of origin. The larger head arises fleshy from the acromion process of the scapula for a distance of about 10 mm., and by a strong aponeurotic band from the antero-inferior edge of the acromion process. The smaller head arises from the os humeroscapulare, a small sesamoid encapsulated by the anconal portion of the capsule of the scapulohumeral joint. The two heads fuse almost immediately and insert fleshy on the anconal surface of the deltoid crest and the shaft of the humerus for a distance of 15 mm. distal to the crest, or for a total distance of 25 mm. Thus, there is a single, continuous, fleshy insertion.

M. DELTOIDEUS MINOR (fig. 4)

This fleshy muscle is about 10 mm. in length. It arises on the inside of the triosseal canal from the lateral surface of the furculum and from the inferior furcular process of the coracoid. The belly leaves the dorsal opening of the canal posterior in position to the tendon of *M. supracoracoideus*, and it inserts semitendinous on the antero-anconal surface of the humerus at the junction of the head and the deltoid crest.

M. PROSCAPULOHUMERALIS (figs. 3, 4)

This fleshy muscle is about 14 mm. in length. It arises from an area 4 mm. wide on the lateral aspect of the scapula immediately caudal to the posterior glenoid lip and the area of origin of *M. scapulotriceps*. It inserts fleshy on an area about 2 mm. long in the pneumatic fossa between the internal and external heads of *M. humerotriceps*.

M. SUBSCAPULARIS

The subscapularis has two heads which are separated by the anterior portion of the aponeurosis of insertion of *M. serratus posterior*. The external head arises from the lateral surface of the scapula for a distance of 7 mm., beginning about 5 mm. caudal to the posterior glenoid lip. It lies between the areas of origin of *Mm. proscapulo-humeralis* and *dorsalis scapulae*. The internal more extensive head arises from the medial surface of the scapula, beginning opposite the glenoid fossa and extending caudad for 18 mm. The two heads fuse and insert by a short stout tendon on the proximal surface of the internal humeral tuberosity near its base. The insertion does not extend into the capital groove.

M. DORSALIS SCAPULÆ (fig. 4)

This strong muscle arises primarily by fleshy fibers from the lateral surface and by an aponeurosis from the ventral surface of the posterior 25 mm. of the scapula, posterior and dorsal to the origin of the lateral head of *M. subscapularis*. It overlaps all but the anterior 2 mm. of the latter muscle. *M. dorsalis scapulae* inserts by fleshy fibers, surrounded by a dense fascial envelope, on the anconal surface, proximal end, of the bicipital crest distal to the origin of the humeral tendon of *M. biceps brachii* and opposite the pneumatic foramen.

M. STERNOCORACOIDEUS (fig. 2)

This muscle arises mostly by fleshy fibers from the lateral surface of the sternocoracoid process of the sternum and from the terminal 4 mm. of the sternal ribs at their costosternal articulation. It inserts mostly by fleshy fibers on the sternocoracoid impression on the posterior surface near the base of the coracoid.

M. SUBCORACOIDEUS (fig. 2)

This muscle arises by two distinct heads. The smaller coracoid head consists of a fleshy bundle about 12 mm. in length. It arises from the coracoclavicular membrane adjacent to the coracoid (but apparently not from that bone) 5 mm. superior to the base of that bone. The larger furcular head is triangular in shape, being widest at its origin over an area 10 mm. long on the medial surface of the furculum immediately inferior to the origin of *M. tensor patagii brevis*. The belly (about 12 mm. long) passes backward and outward to fuse with the coracoid head about 5 mm. from the point of insertion. A single, short, stout tendon forms and inserts on the posterior surface of the internal humeral tuberosity proximal to the origin of *M. biceps brachii*.

M. SERRATUS POSTERIOR

This muscle consists of three main fasciculi plus a dermal component. The anterior slip arises from the last cervicodorsal rib ventral to its uncinat process. About 3 mm. inferior to the scapula, the fleshy fibers give way to a broad aponeurotic sheet which inserts on the ventral edge of the scapula beginning about 5 mm. caudal to the posterior glenoid lip and extending caudad to the fleshy insertion of the two posterior slips of the muscle. Anteriorly, this aponeurosis passes between the two heads of *M. subscapularis*. The two posterior slips arise, respectively, from the uncinat processes of the first and second true ribs. These two slips insert fleshy on the posterior 6 mm. of the apex of the scapula and by a thin aponeurosis which is continuous with that of the anterior slip. There is, thus, a continuous insertion on the ventral edge of the scapula on its posterior 29 mm.

The dermal component arises from the second true rib on a level with its uncinat process. It inserts into the skin at the posterior margin of the humeral feather

tract, slightly posterolateral to the insertion of the dermal component of *M. latissimus dorsi*.

M. SERRATUS ANTERIOR

This muscle arises by two fleshy fasciculi, one from the last cervicodorsal rib dorsal to the uncinat process, and the other from the upper half of the first cervicodorsal rib. The two fleshy slips insert together on the medial surface of the scapula immediately posterior to the area of insertion of *M. serratus profundus*.

M. SERRATUS PROFUNDUS

This muscle arises by fleshy fasciculi from the transverse processes of cervical vertebrae 11 and 12. It inserts on the medial aspect of the scapula for a distance of 20 mm., beginning slightly caudal to the middle of the bone.

M. BICEPS BRACHII (figs. 1, 2)

A roughly L-shaped tendon taking attachment from the coracoid and the humerus gives rise to this strong flexor. The stronger part of the tendon arises from the head of the coracoid immediately lateral to the triosseal canal and inferior to the origin of *M. coracobrachialis anterior*. The humeral attachment is by a broad (2 mm.) tendinous band from the posterior face of the base of the internal tuberosity. The length of the fleshy belly is about 32 mm. Two stout round tendons form about 6 mm. above the insertion areas, which are on the bicipital tubercles on the radius and ulna, located 2 mm. and 3 mm., respectively, distal to the proximal articular surfaces of those bones. A biceps slip to the tendon of *M. tensor patagii longus* is wanting.

M. TRICEPS (figs. 1, 2, 3, 4)

The triceps muscle has only two major parts, a scapulotriceps and a humerotriceps, though at the proximal end of the origin the latter may be separated into an internal and an external head. The scapulotriceps arises by a dense fascia on its deep surface and by fleshy fibers superficially from the posterior lip of the glenoid fossa. The internal head arises fleshy from the postero-anconal surface of the humerus beginning 5 mm. distal to the articular head and extending distad 30 mm. Its area of origin lies entirely posterior to the areas of insertion of the two parts of *M. latissimus dorsi*, but anterior to the insertion of *M. proscapulohumeralis*. The external head arises fleshy from the posterior surface of the bicipital crest and the shaft of the humerus to within 6 mm. of the distal end of the bone. Some fibers of the internal head insert on the tendon of the scapulotriceps, which passes through the internal tricipital groove to insert on the proximal end of the ulna anterior to the olecranon process. A strong tendon also forms on the deep surface of the external head and inserts on the olecranon process. Fleshy fibers of the internal head insert on this tendon.

M. EXPANSOR SECUNDARIORUM (fig. 1)

This muscle was described by Garrod (1876: 193-194) who considered it to be of value in classification. So far as I know, this muscle has been described by only one American worker: Burt (1930: 497 and Fig. 15) in *Ceophloeus* (= *Dryocopus*) *pileatus picinus*. Garrod's illustration of this muscle in *Gallinula chloropus* was re-drawn by Shufeldt (1887: 327; 1890: 110). Dr. George E. Hudson informs me (*in litt.*), however, that he has found *M. expansor secundariorum* to be present in all members of the Corvidae which he has examined. Garrod (*op. cit.*, p. 199) spoke of this muscle as being "Ciconine" in the Cuculidae. This is not true of *Coua caerulea*. In this species, the structure of *M. expansor secundariorum* apparently is unlike that in any bird previously described in that it is a double muscle. The larger, deeper part

arises by a strong, flat tendon from the entepicondyle of the humerus, distal to the origin of *M. pronator brevis* and superficial to the other tendons arising there (see Burt, *loc. cit.*, who found this part of the muscle in woodpeckers). It inserts by fleshy fibers on the bases of the distal tertials and secondaries 9 and 10 (outermost counted as first). The superficial portion arises by a broad aponeurosis attached along a narrow line on the dorsomedial edge of the scapula and is fused also with the fascia covering the medial surface of *M. subscapularis*. The aponeurosis tapers to a thin tendon which passes ventrad mesial to the bellies of *Mm. dorsalis scapulae* and *latissimus dorsi pars posticus* and parallel to the humerus. A short distance above the elbow, a 15 mm.-long, fleshy belly forms and passes through the internal tricipital groove to insert on the palmar surface of the bases of secondaries 8, 9, and 10 (this is the part of the muscle described and illustrated for several species by Garrod, Fürbringer, Forbes, and Gadow).

M. BRACHIALIS (fig. 1)

M. brachialis arises over an area about 3.5 mm. long and 1.5 mm. wide from the brachial impression on the palmar aspect of the distal end of the humerus. It inserts over an area 6 mm. long on the brachial impression of the ulna between the areas of origin of *Mm. flexor digitorum profundus* (posterior to it) and *extensor pollicis longus* (anterior). *M. brachialis* is fleshy throughout.

M. EXTENSOR METACARPI RADIALIS (figs. 1, 3)

The single fleshy belly of this muscle is about 30 mm. long. It arises both fleshy (superficially) and tendinous (on its deep aspect) from the ectepicondylar process of the humerus. A strong, flat tendon forms near the distal end of the muscle and passes through the tendinal grooves on the radius and the radiale. It inserts on the extensor process of metacarpal I, superficial and anterior to the insertion of *M. extensor pollicis longus*. *M. abductor pollicis* arises from the tendon of insertion of *M. extensor metacarpi radialis*. *M. tensor patagii brevis* sends a strong fascial band into the muscular fascia covering the belly of *M. extensor metacarpi radialis* 10 mm. distal to its origin.

M. EXTENSOR DIGITORUM COMMUNIS (fig. 3)

This muscle arises tendinous from the lateral supracondylar ridge (i. e., distal to the ectepicondylar prominence) deep to the tendon of origin of *M. flexor metacarpi radialis*. The tendon forms on the deep aspect of the belly, which is about 27 mm. long. The tendon passes through a fibrous canal on the ulnar condyle, where it lies superficial to the tendon of *M. flexor metacarpi radialis*. The tendon bifurcates opposite the base of the pollex. The short tendon inserts on a tubercle on the postero-proximal corner of the pollex. The long tendon runs along the bases of the primaries in a groove on metacarpal II; near the middle of the carpometacarpus it passes deep to the tendon of *M. extensor indicis longus*, to insert on the postero-anconal surface of the proximal phalanx of digit II.

M. SUPINATOR BREVIS (figs. 2, 4)

This is a long thin muscle closely applied to the anterior surface of the radius. It arises tendinous from the lateral supracondylar ridge between the origins of *Mm. anconeus* and *extensor digitorum communis*. The fleshy belly is about 23 mm. long. It inserts fleshy on the anteroproximal surface of the radius beginning 3 mm. from the proximal articular surface and extending distad 21 mm.

M. FLEXOR METACARPI RADIALIS (fig. 3)

This muscle arises by a Y-shaped tendinous band, whose proximal attachment is on the lateral supracondylar ridge proximal to the origin of *M. anconeus* and super-

ficial to the origin of *Mm. extensor digitorum communis* and *supinator brevis*. The distal attachment of the band is on the anconal surface of the ulna about 5 mm. from the proximal articular surface. Fleishy fibers begin 8 mm. from the humeral origin. The fleshy belly is 25 mm. in length and gives way to a stout round tendon at the distal end of the ulna. The tendon passes around the lateral surface of the external condyle in a fibro-osseous canal and inserts on the flexor tuberosity of metacarpal II opposite the proximal limit of the intermetacarpal space.

M. PRONATOR BREVIS (fig. 1)

The most proximal origin of those muscles arising on the posterodistal surface of the humerus is that of *M. pronator brevis*. It arises by a strong, flat tendon proximal to the entepicondylar eminence and the origin of *M. pronator longus*. Fleishy fibers form almost immediately, cross *M. brachialis*, and extend about three-fourths the way down the radius. The total length of the belly is 32 mm. It inserts fleshy on the radius beginning about 2 mm. distal to the biceps insertion and extending to within 9 mm. of the distal end of the bone.

M. PRONATOR LONGUS (fig. 1)

This muscle arises by a strong tendon from the entepicondylar process adjacent to the origin of *M. flexor digitorum sublimis* and under cover of the humeral tendon of origin of *M. expansor secundariorum*. Fleishy fibers arise from the deep surface of the tendon at its origin. The total length of the fleshy belly is 37 mm. The insertion is semitendinous proximally, but fleshy distally, on the ulnar side of the radius beginning 7 mm. from the proximal articular surface and extending to the distal end of the bone. The semitendinous portion of the insertion is shared by the origin of *M. extensor indicis longus*.

M. EXTENSOR POLLICIS LONGUS (figs. 2, 3, 4)

The long extensor of the pollex takes origin from both radius and ulna. It arises from the anterior (radial) surface of the ulna beginning 1 mm. from the proximal articular surface and extending distad 16 mm., and from the ulnar surface of the radius beginning 6 mm. from the head and extending distad 18 mm. The belly fills most of the interval between radius and ulna in the proximal two-thirds, where the belly lies in contact with the interosseous membrane. The tendon forms near the distal end of the ulna and passes through a groove on the radiale to insert on the extensor process of metacarpal I.

M. ANCONEUS (figs. 3, 4)

This muscle arises from the lateral supracondylar ridge immediately distal to the origin of *M. flexor metacarpi radialis* and superficial to the origin of *M. supinator brevis*. The fleshy belly is 25 mm. long. It inserts by fleshy fibers on the anterior surface of the ulna beginning 3.5 mm. distal to the proximal articular surface and extending distad 22 mm. Throughout all but its proximal portion it is separated from *Mm. extensor pollicis longus* and *extensor indicis longus* by the interosseous membrane.

M. EXTENSOR INDICIS LONGUS (figs. 2, 4)

This muscle arises mostly by fleshy fibers from the ulnar surface of the radius beginning 6 mm. from the proximal articular surface and extending distad 24 mm. The tendon forms at the distal end of the ulna, passes through the interval between ulna and radiale, and down the anterior edge of metacarpal II, where it passes superficial to the tendon of *M. extensor digitorum communis*. It inserts on the base of phalanx 2, digit II, between the areas of insertion of *Mm. interosseous dorsalis* and *flexor digitorum profundus*.

M. FLEXOR DIGITORUM SUBLIMUS (fig. 1)

This complicated muscle has a fleshy belly about 20 mm. long. It arises by a cord-like tendon from the entepicondylar process distal to the origin of *M. pronator longus* and under cover of the humeral tendon of *M. expansor secundariorum*. Fleshy fibers begin about 12 mm. distal to the origin of the tendon; about 10 mm. from its origin the tendon fans out to a width of 5 mm., covering the posterior flat surface of the belly. Dorsally, this tendinous sheet attaches to the bases of the eight distal secondaries, and distally it attaches to the base of the ulnare. The main tendon of insertion, however, forms at the level of the ulnare and swings around a fibrous-covered groove on the anterior surface of that bone. On the manus, the tendon grooves the belly of *M. abductor indicis*, and near the distal end of the carpometacarpus it passes deep to the tendon of *M. flexor digitorum profundus*. It inserts on the anteropalmal corner of the base of the proximal phalanx of digit II. Shufeldt (1890) apparently considered this muscle as part of *M. flexor carpi ulnaris*.

M. FLEXOR DIGITORUM PROFUNDUS (figs. 1, 2)

This muscle arises over an area 27 mm. long on the ulna beginning 2 mm. from the proximal articular surface and extending distad to the origin of *M. flexor carpi ulnaris brevis*. In position it lies deep to *M. flexor digitorum sublimus* and superficial to *M. flexor carpi ulnaris brevis*. Its fleshy belly is 33 mm. long. A strong tendon forms at the distal end of the ulna and swings around the anterior surface of the pisiform process, after which it grooves the superficial surface of *M. abductor indicis* in its course distad. It crosses superficial to the flexor digitorum sublimus tendon and then continues along the anteropalmal surface of digit II to insert on the base of its distal phalanx.

M. FLEXOR CARPI ULNARIS (fig. 1)

This is the largest muscle of the forearm. It arises by a short (3 mm. long), stout tendon from the distal end of the entepicondyle of the humerus. At its origin the tendon is surrounded by a fibrous humero-ulnar pulley (Shufeldt, 1890: 142). The heavy fusiform belly extends the entire length of the ulna and inserts on the proximal face of the ulnare. A secondary fleshy belly arises from the deep surface of the tendon of origin and from the humero-ulnar pulley. This belly runs parallel to the main belly and gives off fleshy fibers which insert into the bases of the eight distal secondaries.

The humero-ulnar pulley attaches to the inner aspect of the entepicondyle of the humerus and to the posterior surface of the ulna just distal to the proximal articular surface.

M. FLEXOR CARPI ULNARIS BREVIS (figs. 1, 2)

This is a short muscle 10 mm. in length. It arises primarily from the anterior surface of the ulna beginning at the distal end of the area of origin of *M. flexor digitorum profundus*, *i. e.*, about 9 mm. from the distal end of the ulna. The origin and belly are covered by a dense fascia which also serves as origin for the most distal fibers of *M. flexor digitorum profundus*. The strong, flat tendon passes through a groove on the radiale, under cover of the tendons of *Mm. extensor metacarpi radialis* and *extensor pollicis longus*, and around to the anconal surface of the manus where it inserts on the base of the carpometacarpus adjacent to the area of origin of *M. extensor pollicis brevis*.

M. ABDUCTOR POLLICIS (fig. 1)

This is a well developed and complicated muscle consisting of two parts. The overall length of the fleshy fibers is 11 mm. The larger part arises fleshy from the

superficial surface of the inserting tendon of *M. extensor metacarpi radialis*. A strong tendinous band forms superficially near the middle of the anterior edge of this belly. This tendon-sheet inserts into somewhat more than half of the palmar surface of the pollex and forms a sheath over the deeper belly. The latter part of the muscle arises by a tendon (5 mm. long) from the deep surface of the tendon of *M. extensor metacarpi radialis*. This tendon gives rise to a fusiform belly about 5 mm. long, which inserts fleshy on the basal half of the palmar surface of the pollex.

M. ADDUCTOR POLLICIS (fig. 2)

This small muscle arises semitendinous from the anteropalmal surface of metacarpal II at the base of the extensor process. It inserts semitendinous about mid-length on the posterior ridge of the pollex.

MM. FLEXOR DIGITI III AND FLEXOR BREVIS DIGITI III (figs. 1, 3)

The separation into two muscles of the flexor mass to digit III in *Coua caerulea* seems to me to be an arbitrary matter. Furthermore, this muscle mass shows a closer relationship to *M. flexor metacarpi posterior* than in other genera of cuckoos I have studied. That portion of the muscle mass which may be considered to correspond to *M. flexor digiti III* in other birds arises by a small slip of fleshy fibers from a groove on the posterior surface of metacarpal III near the distal end of that bone. The rest of the muscle mass (*M. flexor brevis digiti III*) arises from the posteropalmal and distal surfaces of metacarpal III over an area about 5 mm. long. The muscle fills the interval between the distal end of metacarpal III and the posterior spine of digit III. Insertion is mostly by fleshy fibers on the posterior surface of digit III including the posterior spine, as well as on the anconal surface of the digit distal to the spine.

M. INTEROSSEOUS DORSALIS (fig. 3)

Lying in the intermetacarpal space, this muscle arises by fleshy fibers from metacarpals II (for a distance of 7 mm.) and III (for a distance of 6 mm.). From a midline raphe, a strong cord-like tendon forms near the distal end of the carpometacarpus and inserts on the base of phalanx 2, digit II, adjacent to the insertion of *M. extensor indicis longus*.

M. INTEROSSEOUS PALMARIS (figs. 2, 4)

Similar in structure to the last described muscle, *M. interosseous palmaris* arises by fleshy fibers over an area 8 mm. long on metacarpal II, and 9 mm. on metacarpal III. The tendon forms as a raphe, passes distad in the interval between digits II and III, and inserts on the posterior surface of phalanx 2, digit II, a short distance beyond the middle of the phalanx. Fleshy fibers cover the tendon to about the level of the posterior spine of digit III.

M. EXTENSOR POLLICIS BREVIS (fig. 3)

This is a well developed fleshy muscle 7 mm. in overall length. It arises from the anconal surface of the extensor process of metacarpal I and from the adjacent area on the base of the carpometacarpus beginning immediately distal to the insertion of the tendon of *M. flexor carpi ulnaris brevis*. It inserts fleshy on the antero-anconal corner of the base of the pollex.

M. ABDUCTOR INDICIS (fig. 1)

This is a strong muscle about 15 mm. in length. It arises by fleshy fibers from the posterior face of the pisiform process and the anterior surface of metacarpal II for a distance of 13 mm. distal to the pisiform process. It inserts mostly tendinous on

the anterior corner of the base of the proximal phalanx of digit II adjacent to the insertion of *M. flexor digitorum sublimus*.

M. FLEXOR POLLICIS (fig. 2)

This is a short (5 mm. long) muscle arising fleshy primarily from the anterior surface of the base of the pisiform process. It is bounded posteriorly by the belly of *M. abductor indicis*. The tendon of *M. flexor digitorum profundus*, in its course around the pisiform process, passes between *Mm. abductor indicis* and *flexor pollicis*. The latter inserts semitendinous on a tubercle on the posterior aspect of the base of the pollex.

M. FLEXOR METACARPI POSTERIOR (figs. 1, 3)

This strong muscle arises by a flat tendinous band from a ridge located about 3 mm. from the distal end of the anconal surface of the ulna. Fleshy fibers cross the wrist joint and insert on the posterior surface of metacarpal III for a distance of 8 mm. Fleshy fasciculi also insert on the bases of the six proximal primaries (1 through 6); a small tendon inserts on the tip of the posterior spine of digit III. The insertion on metacarpal III is closely related to the areas of origin of *Mm. flexor digiti III* and *flexor brevis digiti III*.

LIST OF ABBREVIATIONS USED IN FIGURES 1-4

Abd. in.—Abductor indicis	Flex. p.—Flexor pollicis
Abd. p.—Abductor pollicis	Inter. dor.—Interosseous dorsalis
Add. p.—Adductor pollicis	Inter. palm.—Interosseous palmaris
An.—Anconeus	Lat. dor. P. ant.—Latissimus dorsi pars anterior
Bic.—Biceps brachii	Lat. dor. P. post.—Latissimus dorsi pars posterior
Cb. ant.—Coracobrachialis anterior	Pect.—Pectoralis superficialis
Cb. post.—Coracobrachialis posterior	Pro.—Proscapulothoracalis
Del.—Deltoideus major	Pro. brev.—Pronator brevis
Del. min.—Deltoideus minor	Pro. long.—Pronator longus
Dor. scap.—Dorsalis scapulae	Rhom. pro.—Rhomboides profundus
Ex.—Expansor secundariorum	Rhom. sup.—Rhomboides superficialis
Ext. dig.—Extensor digitorum communis	Sub.—Subcoracoideus
Ext. in. l.—Extensor indicis longus	Sup. brev.—Supinator brevis
Ext. meta.—Extensor metacarpi radialis	Supra.—Supracoideus
Ext. p. brev.—Extensor pollicis brevis	Stern.—Sternocoracoideus
Ext. p. long.—Extensor pollicis longus	T.—Triceps
F. c. u.—Flexor carpi ulnaris	T. ext.—Triceps external head
F. c. u. brev.—Flexor carpi ulnaris brevis	T. int.—Triceps internal head
Flex. d. III—Flexor digiti III and Flexor brevis digiti III	T. p. b.—Tensor patagii brevis
Flex. dig. pro.—Flexor digitorum profundus	T. p. l.—Tensor patagii longus
Flex. dig. sub.—Flexor digitorum sublimus	Tr.—Triceps scapular head
Flex. meta.—Flexor metacarpi radialis	
Flex. meta. post.—Flexor metacarpi posterior	

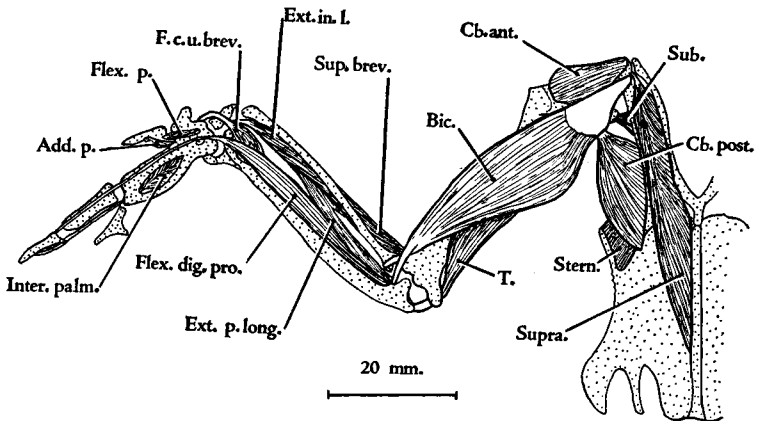
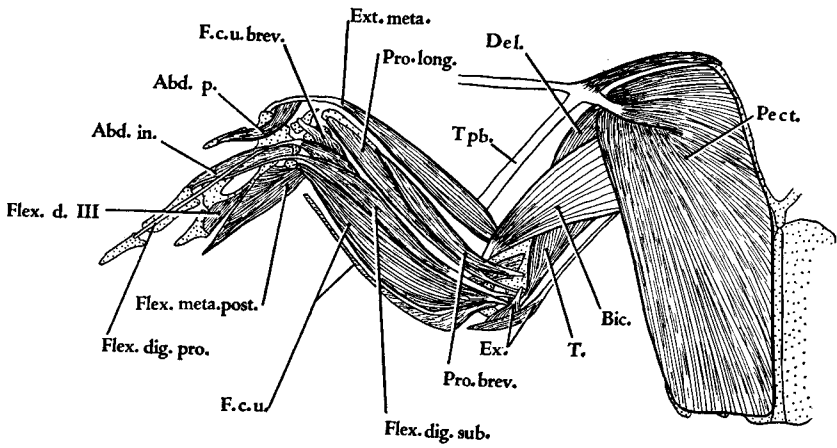


FIGURE 1. (Top) *Coea caerulea*. Superficial muscles of the palmar surface of the right wing and pectoral region.

FIGURE 2. (Bottom) *Coea caerulea*. Palmar view showing a second layer of muscles.

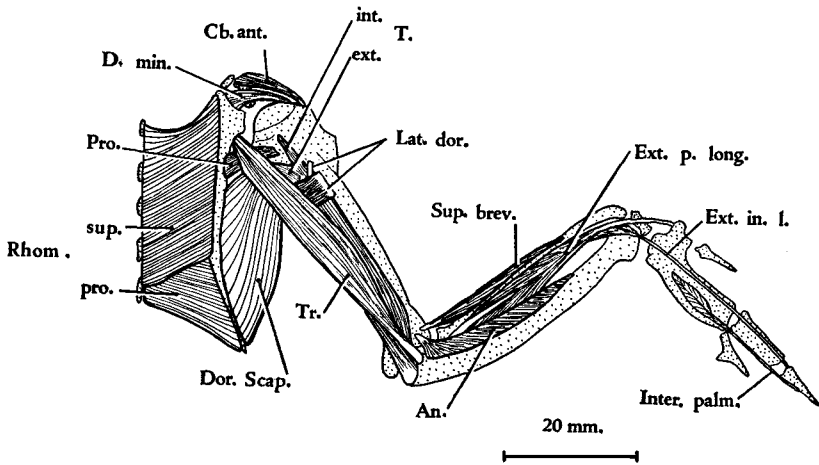
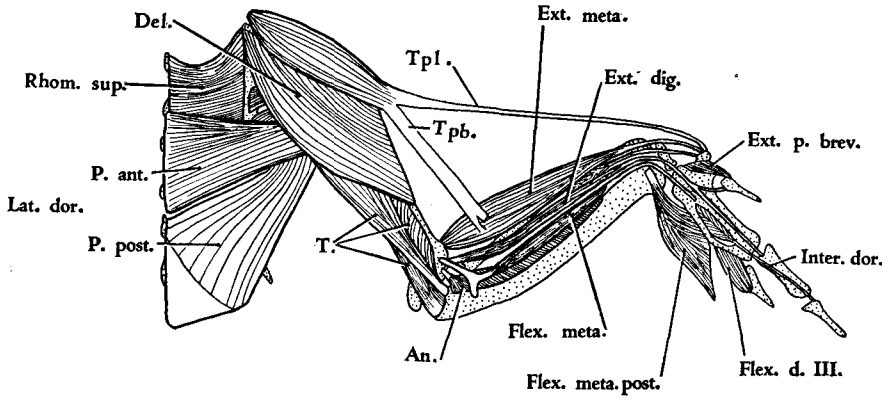


FIGURE 3. (Top) *Coua caerulea*. Superficial muscles of the anconal surface of the right shoulder and wing.

FIGURE 4. (Bottom) *Coua caerulea*. Anconal view showing a second layer of muscles.

DESCRIPTION OF LEG MUSCLES

M. ILIOTROCHANTERICUS POSTICUS (fig. 6)

The area of origin of this muscle covers the entire anterior iliac fossa, extending from the median dorsal ridge to the ventral margin of the ilium immediately dorsal to the origin of *M. iliотrochantericus anticus*. The origin is fleshy from the anterior iliac fossa, the posterior surface of the anterior iliac process, the median dorsal ridge, and the anterior iliac crest to a point dorsal to the center of the acetabulum. Fleshy fasciculi also arise from the superficial aponeurosis covering *M. iliотrochantericus anticus*. *M. iliотrochantericus posticus* inserts by a 3 mm.-wide, heavy tendon on an elevation on the lateral surface of the femur immediately distal to the trochanter.

M. ILIOTROCHANTERICUS ANTICUS (figs. 6, 7, 8)

This muscle arises by fleshy fibers on its deep surface, and by a dense aponeurosis on its superficial surface, from the posterior face of the anterior iliac process (See Berger, 1952: 516) and the ventrolateral edge of the ilium for a distance of 10 mm. The belly tapers to a width of 2.5 mm. at the femur where it inserts by a 3 mm.-long tendon on a tubercle 7 mm. distal to the trochanter.

M. ILIACUS

I did not find this muscle in either specimen. There is, however, a strong, fibrous ligament which attaches to the lateral surface of the ischium dorsal to the base of the pectineal process and immediately in front of the anterior rim of the acetabulum. Its other attachment is to the medial surface of the femur about 2 mm. distal to the trochanter and similar in position to the insertion of *M. iliacus* in other cuckoos I have examined. That this ligament represents *M. iliacus* is open to question.

M. AMBIENS (figs. 7, 8)

The ambiens muscle is the most mesial muscle on the anteromesial aspect of the thigh. It is a strap-like muscle whose fleshy belly is 38 mm. long and 7 mm. in maximum width. It arises by a band-like aponeurosis over an area 2.5 mm. wide from the pectineal process, with some fleshy fibers arising from the lateral surface of that process. Near the proximal surface of the patella the belly tapers to a flat tendon which enters the patellar tendon and passes diagonally downward and laterad around the front of the knee. About 6 mm. distal to the fibular head, the tendon fuses with a broad tendinous band formed as a ventral prolongation of the proximal and third arms of the biceps loop. The resulting complex runs distad for a total distance of 35 mm. and serves as the sole origin for the anterior head of *M. flexor perforatus digiti IV* and serves as a tendon of origin for fleshy fibers of *Mm. flexores perforati digiti II* and *III*.

M. SARTORIUS (fig. 5)

The sartorius muscle is a long strap-shaped muscle arising by a short aponeurosis from the anterior 7 mm. of the median dorsal ridge and from the tendons of *M. longissimus dorsi* dorsal to the fourth dorsal vertebra, but does not arise directly from its neural spine. The belly is intimately fused with the anterior edge of *M. iliотibialis* in its proximal half. *M. sartorius* inserts fleshy on the anteromesial edge of the patellar tendon beginning at the level of the sesamoid, and it also inserts on the superior surface of the inner cnemial crest.

M. ILIOTIBIALIS (figs. 5, 8)

This is the most expansive muscle of the thigh. It covers all other muscles on the lateral aspect except for parts of *Mm. semitendinosus*, *semimembranosus*, *pars*

caudofemoralis of the piriformis, and sartorius. It arises by an aponeurosis attached along a curved line on the anterior iliac process, the median dorsal ridge, and the anterior iliac crest, and both fleshy and semitendinous (on the deep surface) from all but the posterior 5 mm. of the lateral surface of the posterior iliac crest. The muscle is fleshy in its anterior and posterior portions, the middle of the latter being about six times as thick as the sheet-like anterior portion. A thin aponeurotic sheet (32 mm. long and 8 mm. in maximum width) lies between the fleshy portions in the distal two-thirds of the muscle. The tendon of *M. iliobtibialis* contributes to the patellar tendon which inserts on the rotular crest of the tibiotarsus.

M. FEMOROTIBIALIS EXTERNUS (fig. 6)

This muscle may be considered to have two heads although the areas of origin are continuous. It arises fleshy from the entire lateral surface of the femur, beginning on a level with the insertion of *M. ilioprochantericus anticus* and extending distad to the proximal attachment of the biceps loop. The anteromedial portion of the belly is fused throughout most of its extent with *M. femorotibialis medius*. The tendon of *M. femorotibialis externus* contributes to the formation of the patellar tendon. What may be considered a second portion of this muscle complex arises by fleshy fibers and by a dense aponeurosis along a narrow area on the distal half of the femur lateral to the area of insertion of *M. accessorius*. The fleshy fibers form a separate head whose tendon contributes to the posterolateral portion of the patellar tendon.

M. FEMOROTIBIALIS MEDIUS (figs. 6, 8)

This muscle arises tendinous from the trochanteric ridge and the femur distal to it, and fleshy from the anterior surface of the femur extending from its proximal end to the attachment of the proximal arm of the biceps loop. Except at their proximal origins, where they are separated by *M. ilioprochantericus anticus*, *M. femorotibialis externus* and *medius* are intimately fused. The fleshy fibers of the latter muscle insert on the entire proximal surface of the patella, while its tendon contributes to the formation of the patellar tendon.

M. FEMOROTIBIALIS INTERNUS (fig. 8)

This muscle arises from the medial surface of the femur beginning 10 mm. inferior to the trochanter and extending distad to within 7 mm. of the distal end of the internal condyle. This area of origin lies between the area of origin of *M. femorotibialis medius* and the area of insertion of *M. adductor longus et brevis, pars interna*. Two separate tendons form and these insert side by side on a tubercle on the proximal corner of the head of the tibiotarsus. The anterior tendon is derived from the proximal fibers of origin, the posterior tendon from the distal fibers.

M. PIRIFORMIS (figs. 5, 6, 7)

The piriformis muscle is composed of two parts.

1. *Pars iliobfemoralis* is a bulky muscle arising fleshy from the ventral surface of the projecting posterior iliac crest for a distance of about 12 mm. beginning immediately caudal to the ilio-ischiatic fenestra. It inserts by fleshy fibers on the posterolateral surface of the femur for a distance of 7 mm. beginning 8 mm. distal to the trochanter.

2. *Pars caudofemoralis* is a thin, strap-like muscle which arises by a tendinous band (4 mm. long) from an area 5 mm. wide on the lateral edge of the disc of the pygo-style. The total length of the muscle is about 45 mm., its maximum width near midlength, 8 mm. About four millimeters from the femur, the fleshy fibers give way to a 3 mm.-wide, thin tendinous band which inserts on a diagonal ridge medial

to, but in contact with, the distal insertion area of pars iliofemoralis. The most inferior portion of this tendon sweeps around the inferior margin of pars iliofemoralis to form a much heavier tendinous insertion.

M. SEMITENDINOSUS (figs. 5, 8)

This is the bulkiest muscle in the thigh. It arises primarily by fleshy fibers from the ventral surface of the projecting posterior iliac crest in its caudal 12 mm. The anterior edge of the belly is very thin, but the posterior portion is about 7 mm. thick. The belly passes downward, forward, and outward to the femur. About 13 mm. from that bone, the belly is separated by a ligamentous raphe from a second fleshy belly which has been called *M. accessorius semitendinosi* (Figs. 6, 7, 8). The latter muscle inserts by fleshy fibers over a distance of 14 mm. on the posterolateral surface of the femur extending distad to the proximal end of the internal condyle. This insertion is lateral to the area of insertion of the distal two-thirds of *M. adductor longus et brevis pars externa*. The fascial plane between the insertion of the accessorius and the origin of pars media of *M. gastrocnemius* is indistinct.

The ligamentous raphe bifurcates at the inferior margin of the belly of *M. semitendinosus*. The superior band (2 mm. wide) continues the same straight course of the raphe and inserts on a ridge on the posteromedial edge of the tibiotarsus 5 mm. distal to its head, where it lies under cover of the tibial attachment of the medial femorotibial ligament. Thus, the superior band crosses medially over the belly of pars media of *M. gastrocnemius*. The inferior band (2.5 mm. wide) turns sharply downward, crosses the belly of pars media of *M. gastrocnemius*, and inserts into the fascia covering it, just above the point of fusion of pars media and pars interna of *M. gastrocnemius*.

I found a strong fibrous connection between *Mm. semitendinosus* and *biceps femoris* near the region of formation of their tendons.

M. SEMIMEMBRANOSUS (figs. 5, 6, 7, 8)

This muscle arises by an aponeurosis from the posterior 15 mm. of the ventral edge of the ischium about 3 mm. dorsal to the ischiopubic fenestra. Fleshy fibers form almost immediately in the posterior region of the aponeurosis, but anteriorly their area of origin recedes distad 14 mm.; the anterior 5 mm. of the aponeurosis serves solely for the origin of fleshy fibers of the more superficial and anteriorly located *M. adductor longus et brevis, pars externa*. Just before entering the crus between pars interna and pars media of *M. gastrocnemius*, the belly of *M. semimembranosus* gives way to a flat aponeurotic sheet, about 4 mm. wide and 11 mm. long, which inserts on a curved ridge immediately inferior to the inner cnemial crest. A separate tendinous band passes from the inferior margin of the main tendon at its formation to insert into the fascia of pars interna of *M. gastrocnemius*. The belly also is connected with *M. semitendinosus* by a short, strong, fibrous band.

M. BICEPS FEMORIS (figs. 6, 7)

The biceps muscle arises by an aponeurosis from the entire anterior iliac crest and the posterior portion of the median dorsal ridge; this aponeurosis is adherent to the dense fascia covering the superficial surface of *M. iliopsoas*. The biceps muscle also arises by fleshy fibers from the ventral surface of the anterior 7 mm. of the posterior iliac crest, extending caudad to the origin of *M. semitendinosus*. The heavy fleshy belly tapers to a tendon which passes through the biceps loop behind the knee. The strong round tendon inserts on a tubercle on the posterior face of the fibula 16 mm. distal to its head. The tendon passes superficial to the belly of *M. flexor perforatus digiti IV* and deep to that of *M. flexor perforans et perforatus digiti II*.

The proximal arm of the biceps loop (12 mm. long) attaches laterally to a ridge 10 mm. from the distal end of the femur. The distal arm attaches to a tubercle about 5 mm. from the distal end of the fibular condyle. The latter attachment is shared with the origin of the lateral head of pars externa of *M. gastrocnemius*. A third arm of the biceps loop is present and is similar in structure to that described for other genera of cuckoos (Berger, 1952).

M. ISCHIOFEMORALIS (figs. 6, 7)

This is a wide bulky muscle arising from nearly the entire lateral surface of the ischium beginning at the posterior margin of the obturator foramen and extending to the caudal end of the bone. The upper margin of the belly parallels the area of origin of *M. piriformis*, pars iliofemoralis and is separated from it only by an aponeurosis. Its lower margin extends to the origin of *Mm. semimembranosus* and adductor longus et brevis, pars externa. A tendinous sheet forms on the superficial surface of the belly of *M. ischiofemoralis* in its middle third. Insertion is by an unusually strong tendon (4 mm. long and 2.5 mm. wide) on a diagonally placed ridge on the femur immediately proximal to the area of insertion of *M. iliотrochantericus anticus*. *M. ischiofemoralis* inserts on the posterosuperior face of this ridge, while *M. iliотrochantericus anticus* inserts on its antero-inferior face.

M. OBTURATOR EXTERNUS

This is a bulky muscle which has a continuous origin from the ventral, anterior, and dorsal margins of the obturator foramen. Its fibers surround the tendon of *M. obturator internus*, but none of its fibers appear to insert on that tendon. The main area of insertion, by fleshy fibers, is medial to the obturator ridge and immediately distal and mesial to the area of insertion of the tendon of *M. obturator internus*. Some of its fibers insert by a thin aponeurosis dorsal and anterior to the tendon of the latter muscle.

M. OBTURATOR INTERNUS (fig. 8)

This is a triangular muscle arising fleshy from the medial surface of the pubis and ischium beginning at the posterior margin of the obturator foramen and extending caudad to within 5 mm. of the posterior end of the ischium, but extending ventrally to the ischiopubic junction. It arises also by a large head from the ventral and medial surfaces of the ilium inside the pelvis. This belly fills about half of the ilio-ischiatic fenestra. A separate tendon forms from this belly and passes through the obturator foramen before fusing with the larger main tendon. Two distinct tendons form on the remainder of the belly, one from the fibers arising from the pubis, the other from the fasciculi arising from the ischium; these tendons fuse in their course through the obturator foramen. The muscle inserts by a single, large, round tendon on the posterolateral edge of the femur about 2 mm. distal to the trochanter. The superficial surface of the ischial portion of the muscle is covered by a dense fascia which continues into the tendon. Apparently none of the fleshy fibers arise from the ischiopubic membrane.

M. ADDUCTOR LONGUS ET BREVIS (figs. 7, 8)

As in most birds this muscle consists of two distinct parts.

1. *Pars externa* is a bulky muscle which arises fleshy in the region of the ventral edge of the ischium for a distance of 10 mm. beginning at the posterior margin of the obturator foramen. Most of its fibers, however, actually arise from the aponeuroses of *Mm. semimembranosus* and adductor longus et brevis, pars interna. The belly

passes downward and forward to insert on the posterolateral surface of the femur for a distance of 24 mm. beginning just distal to the insertion of *M. piriformis*.

2. *Pars interna* is a thinner muscle which arises by a dense aponeurosis from an area 11 mm. long on the ventral edge of the ischium at the dorsal margin of the ischiopubic fenestra, beginning at the posterior margin of the obturator foramen. Fleshy fibers form almost at once in the anterior third, but the posterior two-thirds remain aponeurotic for about a third (15 mm.) the distance down the thigh. It inserts by an aponeurosis on the posteromedial surface of the femur for a distance of 22 mm., extending to a tubercle on the proximal end of the internal condyle.

M. TIBIALIS ANTICUS (figs. 5, 6, 8)

This is a large muscle (65 mm. in length) lying on the anterior aspect of the crus. It arises by two heads. The larger head arises mostly by semitendinous bands, shared with *Mm. peroneus longus* and *flexor perforans et perforatus digiti III*, from the inner cnemial crest and the rotular crest, and fleshy from the lateral surface of the outer cnemial crest. The smaller head arises by a stout tendon (6 mm. long) from a pit on the anterodistal end of the external femoral condyle. The spindle-shaped belly fuses with the tibial head about 20 mm. inferior to the head of the tibiotarsus. Near the distal end of that bone, the stout tendon passes under the heavy ligamentum transversum in company with, but superficial to, the tendon of *M. extensor digitorum longus*. The tendon inserts on a tubercle on the anterior surface of the tarsometatarsus 5 mm. inferior to the proximal articular surface of that bone. At its insertion, the tendon lies between the tendon of *M. extensor digitorum longus* (medially) and the belly of *M. extensor brevis digiti IV* (laterally).

M. EXTENSOR DIGITORUM LONGUS (figs. 7, 8)

This muscle arises fleshy from the lateral surface of the inner cnemial crest, the anterior surface of the outer cnemial crest, and from the anterolateral surface of the tibiotarsus for a distance of about 15 mm. Fleshy fibers extend to within 17 mm. of the distal end of the bone. The tendon forms on the posterior margin of the belly, passes under the ligamentum transversum deep to the tendon of *M. tibialis anticus*, and then under a bony bridge immediately above the condyles. It passes through a fibro-osseous canal on the anteromedial surface of the tarsometatarsus just below its head, where it lies medial to the tibialis anticus tendon and lateral to *M. extensor hallucis longus*. A short distance above the distal end of the tarsometatarsus, the tendon expands to a width of 7 mm. From the distomedial corner of this expanded sheet, two tendons (one ensheathed by the other for a short distance) pass down the extensor surface of digit II. The medial tendon inserts on the proximal ends of phalanx 2 and the unguis phalanx, whereas the more lateral tendon inserts on the proximal end of the unguis phalanx only. Four tendons pass down the extensor surface of the proximal phalanx of digit III. One inserts on the proximal end of phalanx 2, another on the proximal end of phalanx 3, and the other two on the unguis phalanx. A single broad tendon passes down the dorsal surface of phalanges 1 and 2 of digit IV, after which two separate tendons continue to the proximal end of the unguis phalanx. Attachments are made to the proximal ends of phalanges 2, 3, 4, and the unguis phalanx.

A strong fibrous automatic extensor ligament arises, under cover of the extensor tendon, about the middle of the subterminal phalanges of digits II, III, and IV. These insert on the dorsoproximal surface of the base of the unguis phalanges of those digits. Smaller automatic extensors are present on each phalanx of digit IV.

M. PERONEUS LONGUS (figs. 5, 6)

This muscle arises semitendinous from the outer cnemial crest and the rotular crest, and by a dense fascial sheet (shared with *M. tibialis anticus*) which attaches on the anterolateral surface of the inner cnemial crest and on a long narrow line on the anteromedial aspect of the tibiotarsus for a distance of 50 mm. It arises also from a dense aponeurosis (shared with *M. peroneus brevis*) from the fibula and the tibiotarsus distal to it. There is no fleshy origin from the tibiotarsus, although the fleshy belly extends about three-fourths the distance down the crus. The belly covers all but the most distal portions of *Mm. tibialis anticus* and *peroneus brevis*. The tendon bifurcates 8 mm. from the distal end of the tibiotarsus. The short tendon inserts on the tibial cartilage. The long tendon passes downward and backward, over the tendon of *M. peroneus brevis*, the lateral tibial condyle, and the head of the tarsometatarsus, to fuse with the tendon of *M. flexor perforatus digiti III* about 11 mm. distal to the head of the latter bone.

M. PERONEUS BREVIS (figs. 5, 6)

The fleshy belly of this muscle is about 55 mm. long. It arises by a dense aponeurosis from the anterior surface of the fibula beginning at the level of the biceps insertion and from the tibiotarsus distal to the fibula; and it arises also by fleshy fibers from the lateral surface of the tibiotarsus at the same level and extending distad 50 mm. The tendon forms on the superficial surface of the distal fourth of the belly and passes under a heavy fibrous loop located on the anterolateral surface of the tibiotarsus just above the external condyle. The tendon then runs downward and backward across the external condyle deep to the long tendon of *M. peroneus longus* to insert on a tubercle on the posteroproximal corner of the tarsometatarsus.

M. GASTROCNEMIUS (figs. 5, 8)

The gastrocnemius muscle complex is composed of three main heads.

1. *Pars externa*. As in the three other genera of cuckoos I have studied, *pars externa* arises by two heads. The lateral head arises by a dense tendinous envelope from a tubercle on the proximal end of the fibular condyle of the femur. The tendon is intimately fused with the lateral surface of the distal arm of the biceps loop. The medial head arises by a flat tendon from a tubercle on the proximomedial surface of the external condyle, where it lies medial to the biceps loop. The tendon fans out and passes distad on the medial surface of the belly. Eight millimeters distal to its origin the tendon gives way to a short (14 mm. long) fleshy belly which fuses with the lateral head. The resulting muscle fuses with *pars media* about 25 mm. distal to the femoral origin.

2. *Pars media* arises tendinous from a tubercle on the posteroproximal tip of the internal condyle, and fleshy from a triangular area on the posterior face of the femur immediately above the condyles. This area of origin lies between the insertion areas of *Mm. adductor longus et brevis*, *pars interna* (medial) and the *accessorius semitendinosi* (lateral). It is a small muscle having a total length of 25 mm. and a maximum width of 7 mm. The belly is separated from *pars interna* by the tibial insertions of *Mm. semimembranosus* and *semitendinosus*.

3. *Pars interna* is a well developed muscle covering the anteromedial aspect of the proximal half of the crus and sweeping around to the anterolateral surface to cover part of *M. peroneus longus*. *Pars interna* arises fleshy from the medial edge of the patellar ligament and the entire medial surface of the inner cnemial crest, and from the inferior edge of that crest by a strong aponeurosis which extends down the deep surface of the belly. About 17 mm. inferior to the head of the tibiotarsus, the ac-

cessory tendon of *M. semimembranosus* inserts on the fascia covering the superficial surface of the belly, and immediately below this point *pars interna* and *pars media* fuse. Both *pars interna* and *pars externa* remain fleshy for about two-thirds the distance down the crus.

The conjoined *Tendo Achillis* passes over the posterior surface of the tibial cartilage and inserts on the posterior surface of the hypotarsus and on the posterolateral ridge of the tarsometatarsus for nearly its entire length. By fusing with the deep fascia, it completes a fibro-osseous compartment for the flexor tendons.

M. PLANTARIS

This is a small muscle which arises from the posteromedial surface of the tibiotarsus immediately below the internal articular surface. Its maximum width is 3.5 mm. and 32 mm. distal to its origin it tapers to a fine tendon. Distally the tendon fans out to insert on the deep surface of the proximal end of the tibial cartilage, only the tendons of *Mm. flexor digitorum longus* and *flexor hallucis longus* lying deep to it.

M. FLEXOR PERFORATUS DIGITI II (figs. 6, 7)

The overall length of the fleshy belly of this muscle is about 45 mm. It is not visible until the following muscles have been reflected: *gastrocnemius*, and *flexores perforati digiti III* and *IV*. The muscle takes its origin from the aponeurosis covering the deep surface of *M. flexor perforatus digiti III* and from the deep surface of the *ambiens tendon complex*. The fleshy fibers begin about 15 mm. below the fibular head. The tendon passes downward on the deep surface of *M. flexor perforatus digiti III*, and through a separate fibrous canal on the lateral surface of the tibial cartilage. The tendon passes from lateral to medial across the intertarsal space, in position deep to all of the flexor tendons except the two long flexors. It then passes through a deep fibro-osseous canal on the posteromedial side of the hypotarsus deep to the tendon of *M. flexor perforans et perforatus digiti III* and lateral to the tendon of *M. flexor perforans et perforatus digiti II*. It passes through a separate fibrous canal in the intertrochlear space superficial to the other tendons passing to digit II. The tendon bifurcates near the base of the proximal phalanx of digit II and inserts on both sides of it.

A strong vaginal sheath encloses the flexor tendons of each digit in a fibro-osseous canal. In addition, a strong fibro-elastic band (annular ligament) crosses the plantar surfaces at the bases of digits II and III. These structures serve to hold the tendons close to the bones.

M. FLEXOR PERFORATUS DIGITI III (figs. 6, 7)

This is a large muscle hidden from lateral view through most of its extent by the belly of *M. flexor perforatus digiti IV* and posteromedially by *M. gastrocnemius*. It arises in part from the distal extension of the *ambiens tendon complex*, but the major origin is by a very strong cord-like tendon from the intercondyloid region of the femur. This tendon also serves as origin for some of the fibers of *Mm. flexor hallucis longus* and *flexor perforatus digiti IV*. The tendon fans out into a broad sheet (5.5 mm. wide), which passes down the deep surface of *flexor perforatus digiti III* for a distance of about 50 mm. This sheet serves as the primary origin for *M. flexor perforatus digiti II*.

Fleshy fibers form about 4 mm. below the femoral origin and extend distad for 57 mm. The belly is intimately fused with *Mm. flexores perforati digiti II* and *IV*. The belly tapers to a broad (2 mm.-wide), flat tendon, which is grooved superficially by the tendon of *M. flexor perforatus digiti IV* in its course through the middle compartment of the tibial cartilage and over the posterior surface of the hypotarsus.

The long tendon of *M. peroneus longus* inserts into this tendon about 11 mm. inferior to the head of the tarsometatarsus. This is the largest of the flexor tendons, and it passes through the intertrochlear space superficial to the other flexor tendons. It inserts primarily on each side of the distal end of phalanx 1 but has a small attachment on the proximal end of phalanx 2. About 3 mm. distal to the metatarsophalangeal joint, the tendon bifurcates to permit passage of the long flexor tendon.

A vinculum is wanting between the tendons of *Mm. flexor perforatus digiti III* and *flexor perforans et perforatus digiti III*.

M. FLEXOR PERFORATUS DIGITI IV (figs. 6, 7)

This muscle arises by two heads. The posterior, or femoral, head arises from the stout tendon of origin of *M. flexor perforatus digiti III*, and its belly is intimately fused with that muscle. The anterior head arises from the ambiens tendon complex. The overall length of the fleshy belly is 52 mm., fleshy fibers extending to within 31 mm. of the distal end of the tibiotarsus. The belly covers *Mm. flexores perforati digiti II* and *III*. The tendon forms on the posteromedial surface of the belly and passes through the tibial cartilage in the middle tendinous compartment, where it grooves the tendon of *M. flexor perforatus digiti III*. It maintains this same relationship over the posterior surface of the hypotarsus and in the proximal fourth of the tarsometatarsus. Distally the tendon sweeps around the medial surface of the trochlea for digit IV and through a dense fibrous canal on its distal surface. The tendon does not ensheath the tendon of *M. flexor digitorum longus*, but fans out to insert near the distal end of the proximal phalanx on the plantar and lateral (medial in zygodactyl foot) sides, the plantar attachment being the stronger.

M. FLEXOR PERFORANS ET PERFORATUS DIGITI II (figs. 5, 6)

The length of the fleshy belly of this muscle is 25 mm., of which the proximal 10 mm. are visible superficially. It arises fleshy from the patellar tendon and by a strong aponeurosis which is attached to the patellar tendon and to the lateral surface of the third arm of the biceps loop. A thin band-like tendon forms on the superficial surface of the belly and passes down the leg on the belly of *M. flexor perforatus digiti IV* and under cover of *M. gastrocnemius, pars externa*. The belly lies superficial to the ambiens tendon and the femoral head of *M. tibialis anticus*. The tendon passes through a separate fibrous canal on the posteromedial edge of the tibial cartilage where it is the most medial tendon; it passes through a separate fibrous canal on the medial surface of the hypotarsus, and through another separate fibrous canal in the intertrochlear space deep to the tendon of *M. flexor perforatus digiti II*. The tendon passes through the bifurcated tendon of *M. flexor perforatus digiti II* at the base of the proximal phalanx of digit II, and about the middle of that phalanx the tendon bifurcates to permit passage of the tendon of *M. flexor digitorum longus*. Insertion is on the sides of the base of phalanx 2.

M. FLEXOR PERFORANS ET PERFORATUS DIGITI III (figs. 5, 6)

The total length of the fleshy belly of this muscle is 47 mm., most of which is visible superficially. It arises by fleshy fibers from the patellar tendon and the outer cnemial crest and by a strong aponeurosis (shared with *Mm. peroneus longus* and *tibialis anticus*) from the outer cnemial crest. Proximally, the belly is intimately fused with *Mm. peroneus longus, tibialis anticus, and flexor perforans et perforatus digiti II*. The tendon forms on the posterior edge of the belly and passes diagonally downward from lateral to posteromedial to pass through the medial side of the superficial compartment of the tibial cartilage. The tendon then takes a straight course through a medial fibrous canal on the hypotarsus, where it is lateral

only to the tendon of *M. flexor perforans et perforatus digiti II*. On digit III the tendon passes between the two tendons of insertion of *M. flexor perforatus digiti III*, and near the middle of phalanx 2 the tendon bifurcates to permit passage of the tendon of *M. flexor digitorum longus*. The resulting tendons insert on either side of the base of phalanx 3.

M. FLEXOR DIGITORUM LONGUS (figs. 6, 7)

This is a large muscle situated deeply on the posterior aspect of the crus. Proximally the belly is Y-shaped. Its total length is 60 mm., its maximum width, 9 mm. It arises fleshy from the posterior surface of the head, neck, and shaft of the fibula, and from the entire posterior surface of the tibiotarsus to within 23 mm. of the distal end of that bone. The tendon passes through the tibial cartilage medial to the tendon of *M. flexor hallucis longus* and deep to the other flexor tendons, and through the medial bony canal of the hypotarsus. It then passes down the tarsometatarsus from medial to lateral and under the tendon of *M. flexor hallucis longus*, with which it is united by a vinculum. The greater part of *M. lumbricalis* arises from the tendon of *M. flexor digitorum longus*. The tendon trifurcates opposite metatarsal I to supply digits II, III, and IV. The main areas of insertion are on the bases of the unguis phalanges of these digits, but accessory insertions occur on subterminal phalanges as indicated in Figure 7.

M. FLEXOR HALLUCIS LONGUS (figs. 6, 7)

This muscle arises fleshy from the intercondyloid region of the femur (between the attachments of the tendon of *M. flexor perforatus digiti III* and the distal arm of the biceps loop), from the tendon of *M. flexor perforatus digiti III*, and from the deep surface of the distal and third arms of the biceps loop. The belly is 32 mm. in length. The tendon passes laterally through the deep surface of the tibial cartilage and through the lateral bony canal of the hypotarsus. On the distal half of the tarsometatarsus, the tendon passes from lateral to medial over the tendon of *M. flexor digitorum longus* and is united with it by a long (9 mm.) but perforate vinculum. The tendon is ensheathed by the expanded tendon of *M. flexor hallucis brevis* opposite the metatarsophalangeal joint. It inserts on the proximal end of the unguis phalanx, but there is a small slip given off the deep surface of the tendon to insert on the pad between the proximal and unguis phalanges.

The automatic flexor of the hallux is a tendinous cord which is as large as the tendon of *M. flexor hallucis longus*. It attaches to the wing of the trochlea for digit IV. Distally it passes over the tendon of the long flexor muscle to attach to the medial side of the base of the unguis phalanx.

M. POPLITEUS

This is the most deeply situated muscle on the posterior aspect of the crus, lying deep to and between the fibular and tibial heads of *M. flexor digitorum longus*. Its dimensions are: 6 mm. in length; 5 mm. wide at its origin on the posteromedial surface of the head and neck of the fibula; 3 mm. wide at its insertion on the popliteal ridge on the tibiotarsus a little distal to the origin.

M. EXTENSOR HALLUCIS LONGUS (figs. 6, 7, 8)

The long extensor of the hallux arises fleshy from a long area on the anteromesial surface of the tarsometatarsus beginning immediately below the head and extending distad 35 mm. Its tendon lies adjacent medially to the belly of *M. abductor digiti II*, passes under a fibrous loop on metatarsal I, and bifurcates opposite the base of

the proximal phalanx. The two tendons pass along the extensor surface of the hallux to insert in common on the base of the ungual phalanx.

A strong automatic extensor ligament of the claw of the hallux arises about the middle of the proximal phalanx and inserts with the extensor tendon (Fig. 7).

M. EXTENSOR PROPRIUS DIGITI III (figs. 6, 8)

This short fleshy muscle lies on the anterior surface of the distal half of the tarsometatarsus, between *Mm. extensor brevis digiti IV* and *abductor digiti II*, with which muscles it is intimately fused. The belly is narrow at its proximal origin, but increases in bulk distally. Its origin begins 25 mm. below the head of the tarsometatarsus and extends distad about 22 mm. The fleshy fibers insert on the proximal surface of a sesamoid bone and the broad (3 mm. wide) tendon inserts on the entire dorsal surface of the base of the proximal phalanx of digit III.

M. EXTENSOR BREVIS DIGITI IV (fig. 5)

This is the largest muscle on the anterior aspect of the tarsometatarsus. It arises fleshy from the anterolateral surface of that bone beginning just below the proximal articular surface and extending distad for 40 mm. The tendon forms as a band-like tendinous raphe, but becomes extremely strong at the distal end of the tarsometatarsus, where it passes through a fibro-osseous canal around the anterior surface of trochlea IV. It inserts on the entire medial (lateral in zygodactyl foot) surface of the base of the proximal phalanx of digit IV.

M. ABDUCTOR DIGITI II (fig. 8)

This is a short (16 mm. long), fleshy muscle whose origin is on the anteromedial ridge of the tarsometatarsus beginning 20 mm. from the distal end of the trochlea for digit II and extending distad 14 mm. A few fasciculi arise from metatarsal I. The belly is fused laterally with the belly of *M. extensor proprius digiti III*, and medially with that of *M. extensor hallucis longus*. The tendon forms on the superficial surface of the belly and inserts on the dorsomedial corner of the base of the proximal phalanx of digit II.

M. FLEXOR HALLUCIS BREVIS (fig. 8)

The belly of this muscle is 23 mm. in length. It arises fleshy from the medial surface of the hypotarsus and from the posteromedial surface of the tarsometatarsus for a distance of 20 mm. beginning immediately below the head. Near the base of the proximal phalanx of the hallux the tendon becomes a much-expanded fibrous pad which ensheaths the tendon of *M. flexor hallucis longus*. It inserts on the ventromedial corner of the proximal phalanx of the hallux.

M. ADDUCTOR DIGITI II

The belly of this small muscle is 9 mm. in length. It arises fleshy from the ventral midline of the hypotarsus between and deep to the tendons of *Mm. flexor digitorum longus* and *flexor hallucis longus*; it arises also from the posterior sulcus of the tarsometatarsus for a distance of 3 mm. below the hypotarsus. The tendon passes down the posterior sulcus next to the bone and passes through the internal intertrochlear notch to insert dorsolaterally on the base of the proximal phalanx of digit II.

M. LUMBRICALIS

This small muscle arises fleshy primarily from the tendon of *M. flexor digitorum longus* beginning 13 mm. inferior to the hypotarsus; a few fibers arise from the tendon of *M. flexor hallucis longus*. It inserts semitendinously on the fibrocartilaginous joint pulley for digit IV.

M. ABDUCTOR DIGITI IV (fig. 7)

The belly of this muscle is about 20 mm. in length, though a few fibers continue distad along the tendon. It arises fleshy from the distolateral corner of the tibial cartilage, the lateral and ventral surfaces of the hypotarsus, and from the posterolateral surface of the tarsometatarsus for a distance of 16 mm. The tendon passes under a heavy fibrous loop on the base of the trochlea for digit IV and inserts laterally (medially in zygodactyl foot) on the base of the proximal phalanx of digit IV.

SUMMARY

The purpose of this paper is to present details of the appendicular osteology and myology of *Coua caerulea*, an interesting and little known cuckoo. Too few genera of this family have been studied to permit speculation on intergeneric relationships. Until it is possible to study other species of the genus *Coua* it seems unwise to make detailed comparisons with New World genera I have studied. Though *Coua caerulea* may not be typical of the genus, one can say that its limb proportions are closer to those of *Geococcyx californianus* than to those of *Crotophaga sulcirostris* or *Coccyzus erythrophthalmus*. Furthermore, there are few differences between the total appendicular myology of *Coua caerulea* and that of *Geococcyx*.

Three species of *Coua* have 14 cervical vertebrae each, the last two of which possess cervicodorsal ribs. There are 4 dorsal vertebrae, and four ribs articulate with the sternum. The sternum is double-notched. The number of free caudal vertebrae in four specimens of *Coua caerulea* studied varies from 4 to 6. A basal disc is well developed on the pygo-

LIST OF ABBREVIATIONS USED IN FIGURES 5-8

- | | |
|---|--|
| Abd. d. IV—Abductor digiti IV | perforatus digiti III |
| Abd. dig. II—Abductor digiti II | Flex. per. d. II—Flexor perforatus digiti II |
| Acc.—Accessorius semitendinosi | Flex. per. d. III—Flexor perforatus digiti III |
| Add. long. P. ext.—Adductor longus et brevis pars externa | Flex. per. d. IV—Flexor perforatus digiti IV |
| Add. long. P. int.—Adductor longus et brevis pars interna | Gas., P. ext., P. int., P. med.—Gastrocnemius pars externa, pars interna, pars media |
| Auto. ext.—Automatic extensor | Il. tib.—Iliotibialis |
| Auto. flex.—Automatic flexor | Il. troc. ant.—Iliotrochantericus anticus |
| Bic. fem.—Biceps femoris | Il. troc. post.—Iliotrochantericus posticus |
| Bic. loop—Biceps loop | Isch. fem.—Ischiofemoralis |
| Ext. brev. d. IV—Extensor brevis digiti IV | Obt. int.—Obturator internus |
| Ext. dig. I.—Extensor digitorum longus | Per. brev.—Peroneus brevis |
| Ext. hal. I.—Extensor hallucis longus | Per. long.—Peroneus longus |
| Ext. pro. d. III—Extensor proprius digiti III | Pirif. P. caud. fem.—Piriformis pars caudofemoralis |
| Fem. tib. ext.—Femorotibialis externus | Pirif. P. il. fem.—Piriformis pars iliofemorialis |
| Fem. tib. int.—Femorotibialis internus | Sar.—Sartorius |
| Fem. tib. med.—Femorotibialis medius | Semim.—Semimembranosus |
| Flex. dig. I.—Flexor digitorum longus | Semit.—Semitendinosus |
| Flex. hal. brev.—Flexor hallucis brevis | Tib. ant.—Tibialis anticus |
| Flex. hal. I.—Flexor hallucis longus | Tib. cart.—Tibial cartilage |
| F. p. et. p. d. II—Flexor perforans et perforatus digiti II | Vin.—Vinculum |
| F. p. et. p. d. III—Flexor perforans et | |

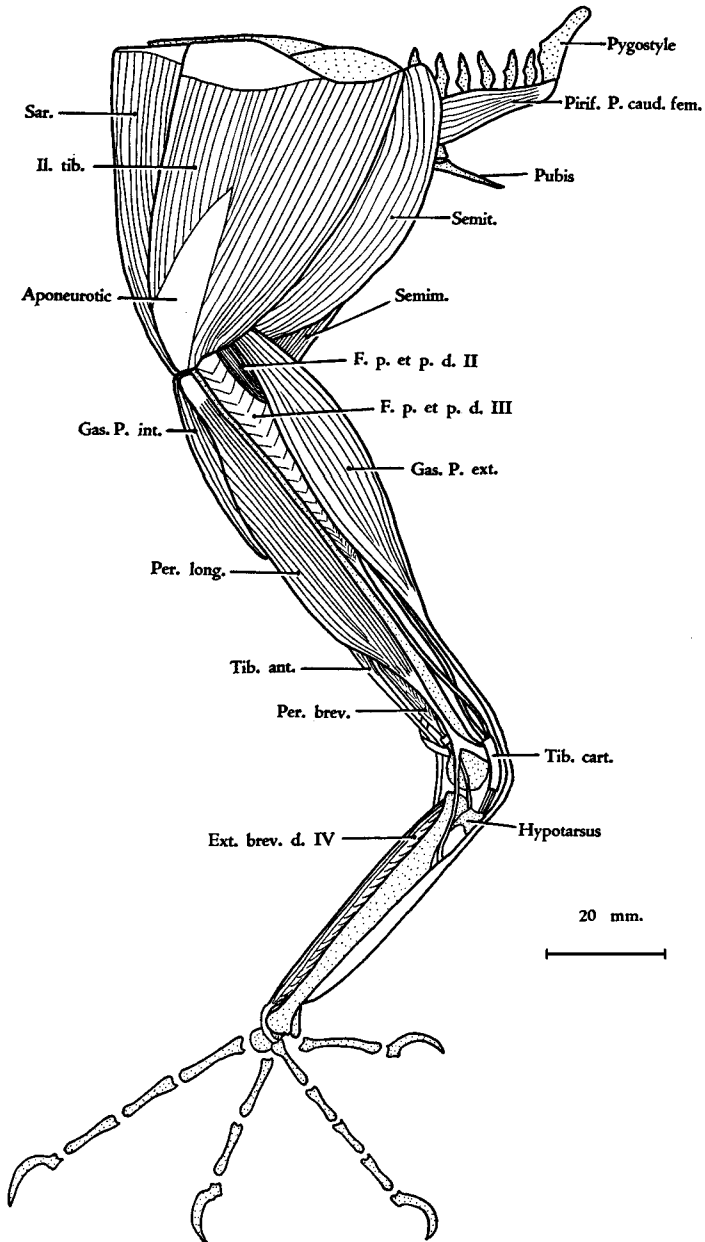


FIGURE 5. *Coua caerulea*. Superficial muscles of the left leg (lateral view).

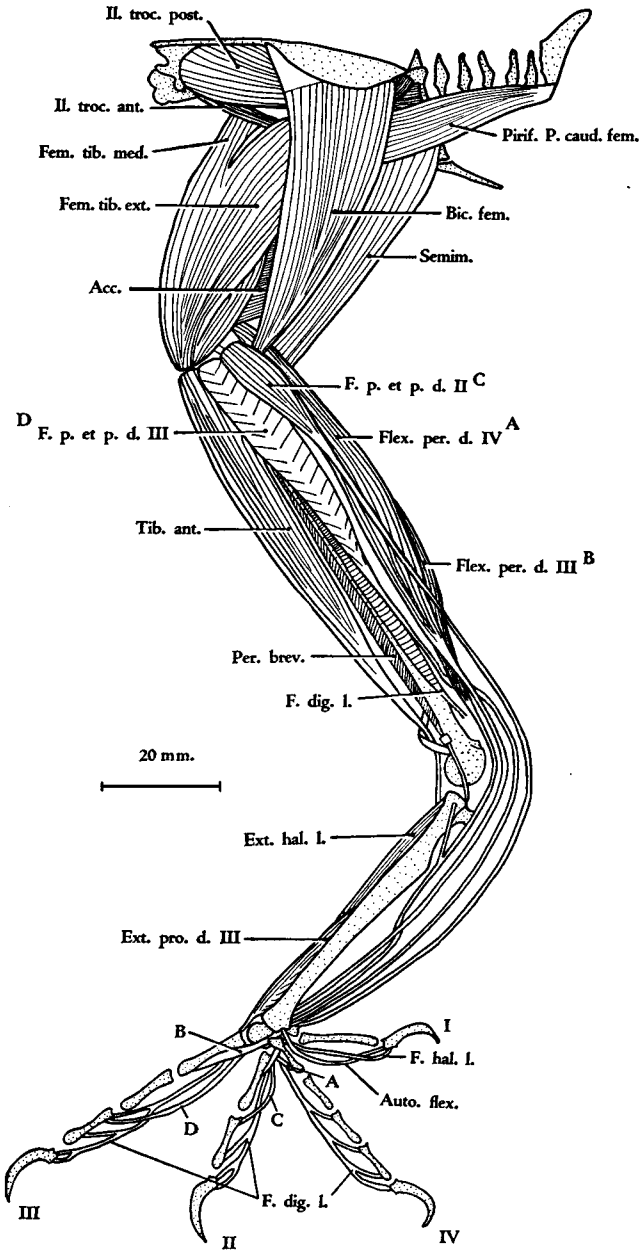


FIGURE 6. *Coua caerulea*. Lateral view of the left leg showing a second layer of muscles.

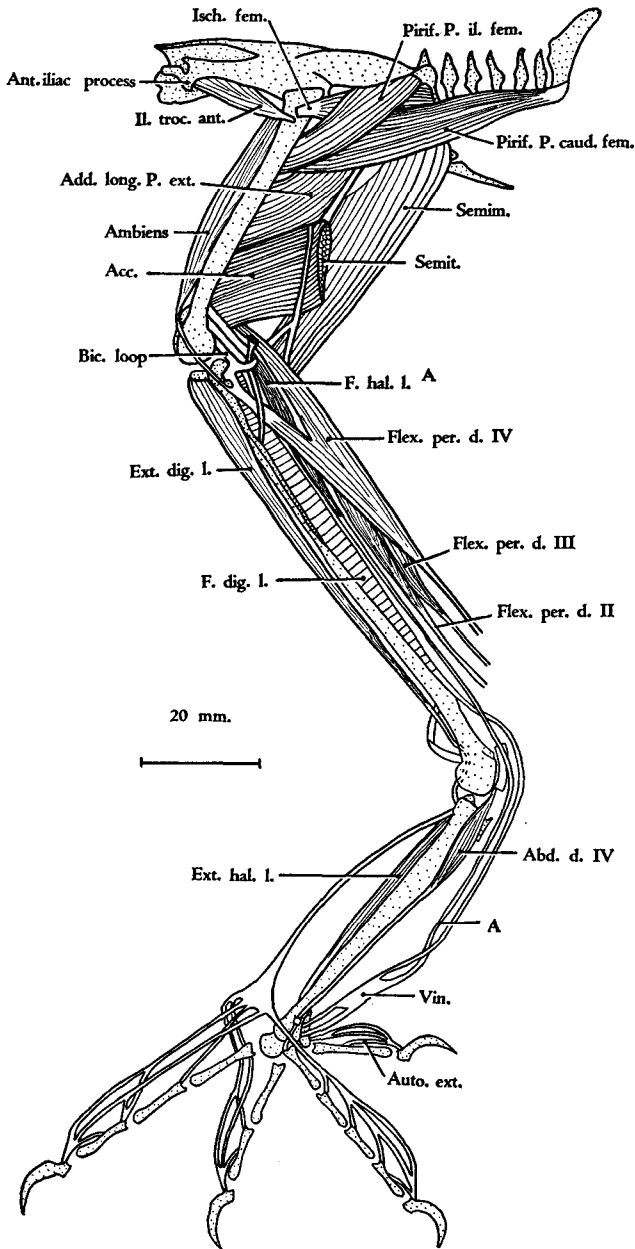


FIGURE 7. *Coua caerulea*. Lateral view of the left leg showing a third layer of muscles.

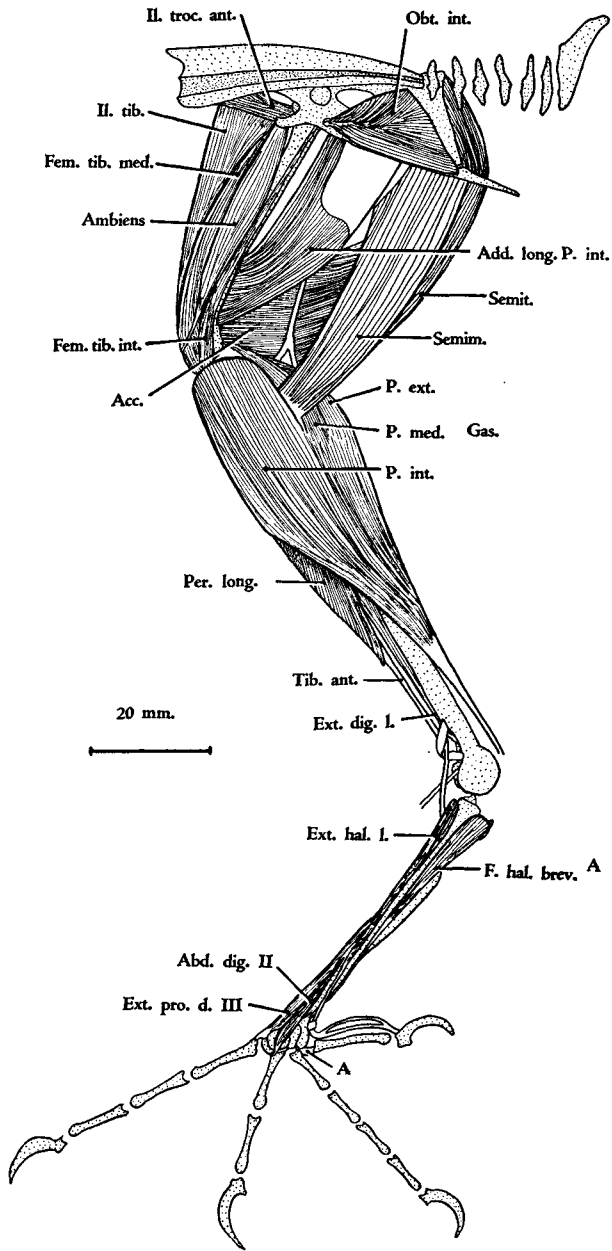


FIGURE 8. *Coua caerulea*. Medial view of the right leg showing the superficial muscles.

style. The bony wing is 50.2 per cent the length of the leg (including digit III), or 62.5 per cent if digit III is excluded. There are two bony canals in the hypotarsus: the lateral canal transmits the tendon of *M. flexor hallucis longus*; the medial canal transmits the tendon of *M. flexor digitorum longus*.

The following wing muscles are absent in *Coua caerulea*: proscapulo-humeralis brevis, flexor metacarpi brevis, abductor indicis brevis, abductor digiti II, and the biceps slip to the tendon of *M. tensor patagii longus*.

A single belly represents *Mm. tensor patagii longus et brevis*, though their tendons of insertion are entirely separate and distinct. *M. deltoideus minor* arises from inside the triosseal canal, rather than from the lateral surface of the acromion process of the scapula. *M. deltoideus major* arises by two heads but has a single continuous insertion. *M. expansor secundariorum* is present and well developed; its structure is unlike that described previously for other birds. *Pars propatagialis musculi cucullaris* (*M. dermo-tensor patagii* of Shufeldt and Fisher) does not insert on the tendon of *M. tensor patagii longus*.

The leg-muscle formula is ABXYAm. The following muscles are wanting: ilirotrochantericus medius, gluteus medius et minimus, iliacus, adductor digiti IV, and extensor brevis digiti III. Especially noteworthy is the absence of *M. iliacus*. A vinculum is present between the tendons of *Mm. flexor digitorum longus* and *flexor hallucis longus*, but a vinculum is wanting between the tendons of *Mm. flexor perforatus digiti III* and *flexor perforans et perforatus digiti III*.

There is a tendinous connection between *Mm. semitendinosus* and *semimembranosus*, and the latter muscle has an accessory insertion on *M. gastrocnemius, pars interna*. *M. obturator internus* is triangular in shape. *M. obturator externus* has a single head. The tendon of *M. flexor hallucis brevis* ensheathes the tendon of *M. flexor hallucis longus*, but the tendon of *M. flexor perforatus digiti IV* does not ensheath the tendon of *M. flexor digitorum longus* supplying digit IV.

LITERATURE CITED

- BEDDARD, FRANK E. 1898. The structure and classification of birds. Longmans, Green and Co., London.
- BERGER, ANDREW J. 1952. The comparative functional morphology of the pelvic appendage in three genera of Cuculidae. *Amer. Midl. Nat.*, 47: 513-605.
- BERGER, ANDREW J. 1953. The pterylosis of *Coua caerulea*. *Wilson Bulletin*, 65: *in press*.
- BURT, WILLIAM HENRY. 1930. Adaptive modifications in the woodpeckers. *Univ. Calif. Publ. Zool.*, 32: 455-524.
- COUES, ELLIOTT. 1903. Key to North American birds. 5th ed., 2 vols., Dana Estes and Co., Boston.

- FISHER, HARVEY IRVIN. 1946. Adaptations and comparative anatomy of the locomotor apparatus of New World vultures. *Amer. Midl. Nat.*, 35: 545-727.
- FÜRBRINGER, MAXMILIAN. 1888. Untersuchungen zur Morphologie und Systematik der Vögel, zugleich ein Beitrag zur Anatomies der Stütz- und Bewegungsorgane. 2 vols. Jena.
- GADOW, HANS, UND EMIL SELENKA. 1891. Vögel, In Bronn's Klassen und Ordnungen des Thier-Reichs. Anatomischer Theil.
- GARROD, ALFRED H. 1876. On the anatomy of *Chauna derbiana*, and on the systematic position of the screamers (Palamedeidae). *Proc. Zool. Soc. London*, 1876: 189-200.
- GARROD, ALFRED H. 1881. The collected scientific papers of the late Alfred Henry Garrod. W. A. Forbes, editor. London.
- HOWARD, HILDEGARD. 1929. The avifauna of Emeryville Shellmound. *Univ. Calif. Publ. Zool.*, 32: 301-394.
- HOWELL, A. BRAZIER. 1937. Morphogenesis of the shoulder architecture: Aves. *Auk*, 54: 364-375.
- HUDSON, GEORGE ELFORD. 1937. Studies on the muscles of the pelvic appendage in birds. *Amer. Midl. Nat.*, 18: 1-108.
- LOWE, PERCY R. 1943. Some notes on the anatomical differences obtaining between the Cuculidae and the Musophagidae, with special reference to the specialization of the oesophagus in *Cuculus canorus* Linnaeus. *Ibis*, 1943: 490-515.
- MILNE-EDWARDS, A., AND A. GRANDIDIER. 1878-1879. Histoire physique, naturelle et politique de Madagascar. vols. 12 and 13. Histoire naturelle des oiseaux. Alfred Grandidier, Paris.
- PYCRAFT, W. P. 1903. Contributions to the osteology of birds. Part VI. *Cuculiformes*. *Proc. Zool. Soc. London*, 1903: 258-291.
- RAND, AUSTIN L. 1936. The distribution and habits of Madagascar birds. Summary of the field notes of the Mission Zoologique Franco-Anglo-Américaine à Madagascar. *Bull. Amer. Mus. Nat. Hist.*, vol. 72, art. 5, pp. 143-499.
- SIBREE, JAMES, JR. 1891. On the birds of Madagascar, and their connection with native folk-lore, proverbs, and superstitions. Part I. *Ibis*, 1891: 194-228.
- SHUFELDT, ROBERT W. 1886. Contributions to the anatomy of *Geococcyx californianus*. *Proc. Zool. Soc. London*, 1886: 466-491.
- SHUFELDT, ROBERT W. 1887. A review of the muscles used in the classification of birds. *Jour. Comp. Medicine and Surgery*, 8: 321-344.
- SHUFELDT, ROBERT W. 1890. The myology of the raven (*Corvus corax sinuatus*). Macmillan & Co., London.

*Department of Anatomy, University of Michigan Medical School,
Ann Arbor, May 8, 1952.*