

## A FACIAL ANOMALY IN A PHEASANT

BY ROBERT M. STABLER

## INTRODUCTION

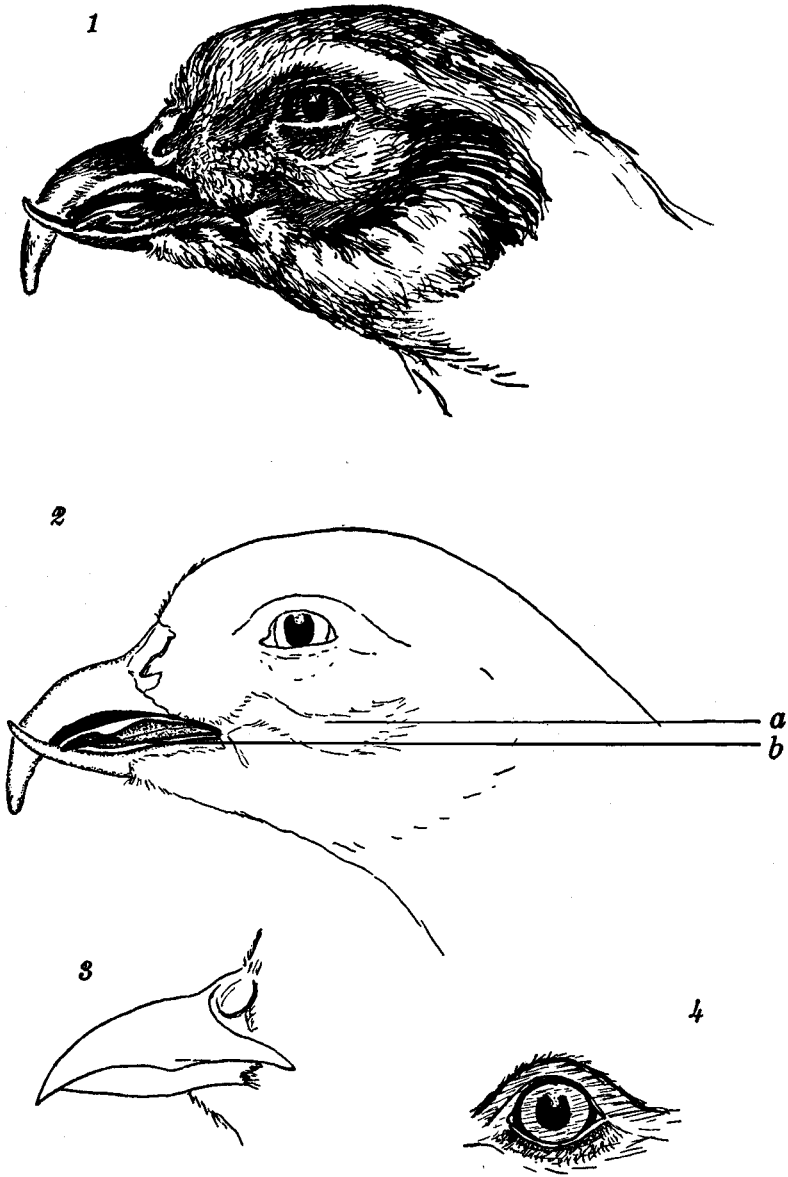
ADJUSTMENTS to accidental mutilations must be much more common in Nature than we realize. The writer has seen wild rabbits with individual feet missing, rats and mice in the same predicament and birds with only a stump where a leg should be. Undoubtedly the reader can likewise recall having seen a wild animal, living apparently happily in its environment, minus an ear, an eye or a leg.

Without going into the literature, it is the writer's desire to present the case of an adult female Chinese Ring-necked Pheasant, *Phasianus torquatus*, collected on March 14, 1938, in Wallingford, Pennsylvania, as part of a survey for protozoan parasites. The condition of this bird, with mandibles permanently crossed and showing other evidences of a serious accident, followed by adjustment, seemed worthy of a note.

The writer wishes to thank Mr. Conrad Roland for the excellent drawing of the head (Text-fig. 1, no. 1). He also wishes to thank Mr. Rodolphe M. De Schauensee of the Philadelphia Academy of Natural Sciences for the use of normal specimens of female Ring-necked Pheasants from the Academy's collection.

## OBSERVATIONS

The pheasant, except for the head region, was apparently a perfectly healthy bird, fat and with a full crop at the time of collection (5.00 p. m.). An examination of the head revealed, first, a pair of irreversibly crossed mandibles, the lower one extending beyond and to the left of the upper (Text-fig. 1, no. 1). These mandibles, having no opposing surfaces to wear them away, had apparently grown almost uninterruptedly at the distal ends. Measurements of the beaks of four normal female birds of the same species showed the following. The average length of the upper mandible from the base of the nares along the curvature to the tip was 20.6 mm., while that for the lower, from the tip back to the feathers of the chin, was 12.0 mm. The corresponding measurements for the present bird were 29.0 and 19.0 mm., respectively. Furthermore, the left side of the upper mandible was considerably worn by the vertical movement of the lower, presumably in eating, while the right side had grown down much lower than normal. Also, most of the mass of the lower mandible had been lost, as it measured only 4 mm. in width half-way out its length, as compared to nearly 10 mm. in the normal bird. The function of the lower mandible was likewise



TEXT-FIG. 1.—Numbers 1 and 2 represent side views of the maimed pheasant; *a* is the bare area on the cheek, *b* is the hardened tip of the tongue. Numbers 3 and 4 represent a normal beak and eye, respectively.

markedly impaired, for the injury had prevented the bird's ever fully opening or closing the mouth.

An examination of the tongue showed another curious modification. It was never completely inside the mouth and, due either to continued friction in eating or to exposure, or both, the distal portion had become very hard and tough and presented the appearance of a thickened, warty termination (Text-fig. 1, no. 2, *b*).

The left side of the cheek itself was also somewhat involved in the mutilation. An area below the eye and just back of the angle of the jaw was completely denuded of feathers (Text-fig. 1, no. 2, *a*), a condition not found on the right side. The muscles of the lower lid of the left eye were somewhat damaged too, and, whereas closure was normal, opening was only three-quarters effective (Text-fig. 1, nos. 1 and 2).

#### DISCUSSION

The question that first comes to one's mind is, How and when did this bird suffer its disfiguring mishap? Obviously the answer can only be founded on speculation. Was the bird in its youth grabbed by a hawk? Bitten by a snake? Mangled in the jaws of a steel-trap? Did Nature alter its appearance before it ever left the egg? Or was it accidentally fired upon by a hunter, leaving the devastating effects of a string of shot on the left side of the face?

Whatever the cause, however, the important point is that the bird had completely compensated for its affliction. Despite its partly closed eye, its scissored, much restricted jaws, it successfully evaded its enemies, fed and drank sufficiently well to maintain itself in the most perfect general physical condition.

*Department of Zoology  
University of Pennsylvania  
Philadelphia, Pennsylvania*