

DISTRIBUTION AND POTENTIAL IMPACTS OF AVIAN POXLIKE LESIONS IN 'ELEPAIO AT HAKALAU FOREST NATIONAL WILDLIFE REFUGE

ERIC A. VANDERWERF

Abstract. I studied distribution of avian poxlike lesions and demography of 'Elepaio (*Chasiempis sandwichensis*) at three sites in Hakalau Forest National Wildlife Refuge on Hawai'i from 1994 to 1997. Birds were mist-netted, banded, visually inspected for lesions, and monitored for survival and reproductive success. Prevalence of avian poxlike lesions in 'Elepaio was much higher at Maulua (40%) at 1,550 m elevation, than at two Pua 'Ākala sites (2%) at 1,800–1,900 m. All infected 'Elepaio had old, healed lesions, not active ones, indicating a past epizootic that had ended. Ages of infected birds revealed that an epizootic occurred at Maulua in 1992; 70% of birds hatched in 1992 or before had healed lesions, but all birds hatched in 1993 or after showed no sign of infection. Birds with healed lesions did not differ from healthy birds in annual survival (0.87 versus 0.86, respectively) or reproductive success (0.71 versus 0.62, respectively), demonstrating that birds surviving the initial infection were no longer affected. 'Elepaio population density at Maulua was 49% lower than at Pua 'Ākala in 1994 (0.66 versus 1.29 birds/ha), but recovered rapidly after the epizootic ended and increased 65% to 1.09 birds/ha by 1996, while density at Pua 'Ākala did not change. As population density increased, more subadults were excluded from the breeding population. Poxlike lesions appeared to reduce numbers of 'Elepaio in certain breeding cohorts at Maulua. The frequency of poxlike epizootics is unknown, but would have important implications for persistence of bird populations in Hawai'i.

Key Words: *Chasiempis sandwichensis*; disease; 'Elepaio; Hawai'i; population reduction; poxlike lesions; reproductive success; survival.

The 'Elepaio (*Chasiempis sandwichensis*) is a small monarch flycatcher that comprises a genus endemic to the Hawaiian Islands of Hawai'i, O'ahu, and Kaua'i. Forms on each island currently are regarded as subspecies (Pratt 1980, Berger 1981, Pyle 1997) but formerly they were treated as separate species (Henshaw 1902b, MacCaughey 1919). 'Elepaio are fairly common and widely distributed at higher elevations on Hawai'i and Kaua'i (Richardson and Bowles 1964, Sincock et al. 1984, Scott et al. 1986), but on O'ahu they have seriously declined in the last few decades and they have a fragmented distribution (Williams 1987, VanderWerf et al. 1997, VanderWerf 1998a). Factors causing the decline of 'Elepaio on O'ahu and limiting their distribution on other islands are not completely understood, but introduced mosquito-borne diseases are one of the primary threats, particularly avian malaria (*Plasmodium relictum*) and avian poxvirus (*Poxvirus avium*; Warner 1968, van Riper et al. 1986, Atkinson et al. 1995, Cann et al. 1996, VanderWerf et al. 1997). The high susceptibility of Hawaiian honeycreepers (Drepanidinae) to avian malaria and avian pox has been well documented by laboratory challenge experiments, and the range of many native Hawaiian birds appears to be limited by these diseases (Warner 1968, Scott et al. 1986, van Riper et al. 1986, Atkinson et al. 1995). However, information is lacking about the effects of disease on the demography of wild populations of Hawai-

ian birds, and the prevalence and distribution of avian pox are not well-known.

Most species of birds are susceptible to at least some of the 13 described species of avian pox (Kirmse 1967, Tripathy 1993). Some species of avian pox are very host specific, especially in wild birds, and pathogenicity can vary considerably among hosts (Tripathy 1993). Poxvirus isolated from one host species can produce severe infection or no reaction at all in other groups of birds, and inoculation with one type of poxvirus may not provide protection against other species of poxvirus (Tripathy 1993). Avian pox symptoms were first observed in Hawaiian birds over a century ago (Henshaw 1902a, Perkins 1903) and now have been found in many species, including 'Elepaio and most other endemic forest birds, several species of seabirds, and several introduced game birds and passerines (van Riper and van Riper 1985). The year when avian pox was introduced to Hawai'i and its place of origin are not clear, and it is possible that more than one species has reached Hawai'i (Warner 1968).

Poxvirus infects a bird through a break in unfeathered skin or in the oral or respiratory mucous membranes, and can be transmitted by either an arthropod bite or by direct contact with a contaminated surface, such as another bird, a perch, or a nest (USFWS 1987, Tripathy 1993). At least 11 species of Diptera have been reported as vectors of avian pox (Akey et al. 1981),

but the principal vector in Hawai'i is the introduced mosquito *Culex quinquefasciatus* (Warner 1968, van Riper et al. 1986, Atkinson et al. 1995). Avian pox infection occurs in two forms. The cutaneous form is characterized by wartlike nodules and tumorous lesions on unfeathered body areas, including the feet, legs, face, and around the bill and eyes. Symptoms of the less common diphtheritic form, or wet pox, include soft yellowish cankers and lesions on membranes of the upper respiratory and digestive tracts and in the mouth (USFWS 1987, Tripathy 1993). Local swellings and lesions first develop at the site where the virus entered; these may increase in size and erupt into granular nodules and tumors, and may be followed by viremia, secondary lesions, and spread to various internal organs (Tripathy 1993). In more severe and advanced cases, lesions may become necrotic and often are accompanied by hemorrhaging and secondary bacterial infections (Warner 1968, van Riper and van Riper 1985, Tripathy 1993). Severity and duration of infection vary considerably among individuals; some birds develop only small lesions and recover rapidly, but others develop very large and debilitating lesions (Warner 1968). Cutaneous lesions on the feet, wings, bill, and eyes can cause difficulty in perching, flight, feeding, and vision, and may inhibit foraging and lead to emaciation and starvation (Docherty et al. 1991, Pearson et al. 1975, Orós et al. 1997). Munro (1960:117) described a Kauai 'Akialoa (*Hemignathus e. procerus*) as being "so disabled with lumps on legs and bill that it could scarcely fly." Diphtheritic lesions on the larynx and trachea can cause respiratory difficulty, gasping, and eventually suffocation, while lesions on the tongue, palate, or esophagus can interfere with eating and drinking (Tripathy 1993). Birds that recover from avian pox often have scars and deformities, such as misshapen or missing claws or digits (Greenwood and Blakemore 1973, Tripathy 1993). The mortality rate may depend on the susceptibility of the host population, the virulence of the avian pox, concurrent physical or environmental stress, and other infections (Tripathy 1993). Avian pox can persist in lesions for up to 13 months (Kirmse 1967), may occur as a latent infection that becomes active again during times of stress (Olsen and Dolphin 1978), and can survive for years in dried scabs (Tripathy 1993).

As part of a long-term study of demography and plumage variation in 'Elepaio, I investigated disease prevalence and monitored survival and reproductive success of 'Elepaio at Hakalau Forest National Wildlife Refuge on Hawai'i Island. Hakalau protects part of one of the largest tracts of native forest left in the state, and it supports

the largest populations of several species of native passerine birds, including 'Elepaio. My objectives were to determine the spatial and temporal distribution of poxlike lesions in 'Elepaio, measure survival and reproduction of 'Elepaio, and understand how poxlike lesions are related to changes in 'Elepaio populations. In particular, previous surveys showed that 'Elepaio and several species of endangered insectivorous honeycreepers were less abundant at Maulua, near the northern end of the refuge, than at Pua 'Akala, at the southern end of the refuge (Scott et al. 1986), but whether disease is a factor in causing this pattern is not known. The 'Elepaio is an especially suitable species in which to study the effects of disease because it is nonmigratory and territorial year-round (VanderWerf 1998a), making it a good indicator of local disease prevalence and easy to find and monitor.

METHODS

STUDY SITE

I conducted this study from 1994 to 1997 at Hakalau Forest National Wildlife Refuge (Hakalau) on the east slope of Mauna Kea on the island of Hawai'i (Fig. 1). Habitat in this region originally was montane rain forest, but some areas were used historically for cattle ranching and logging, resulting in a mosaic of relatively dense, closed-canopy forest and highly disturbed open-canopy woodland. I studied 'Elepaio at three sites on the refuge; a closed-canopy site at middle Pua 'Akala (MPA) at 1,800 m elevation, an open-canopy site at upper Pua 'Akala (UPA) at 1,900 m elevation, and another open-canopy site at Maulua at 1,550 m elevation. The two Pua 'Akala sites were contiguous, but the Maulua site was about 10 km to the north (Fig. 1). At all three sites, 'ohi'a (*Metrosideros polymorpha*) and koa (*Acacia koa*) were the dominant tree species, and other fairly common trees included 'olapa (*Cheirodendron trigynum*), kōlea (*Myrsine lessertiana*), kāwa'u (*Ilex anomala*), and pilo (*Coprosma montana*). Common shrubs included 'ōhelo (*Vaccinium calycinum*), 'ākala (*Rubus hawaiiensis*), and pūkiawe (*Styphelia tameiameia*). Ground cover consisted of native forbs and ferns, and introduced grasses.

STUDY SPECIES

'Elepaio are insectivorous, socially monogamous, nonmigratory, and territorial year-round (Conant 1977, van Riper 1995, VanderWerf 1998a). The foraging behavior of 'Elepaio is extremely varied and plastic (VanderWerf 1994), they are generalized in habitat selection (VanderWerf 1993), and are one of the most successful Hawaiian forest birds in adapting to disturbed habitats and introduced plant species (Conant 1977, VanderWerf et al. 1997). 'Elepaio populations have persisted at low elevations in some areas where most other native birds have disappeared, suggesting 'Elepaio may have greater immunity to introduced diseases than many Hawaiian birds (VanderWerf 1998a). 'Elepaio are sexually mature and sometimes breed when one year old, but have a two-year delay in plumage maturation in both sexes, resulting in distinct first

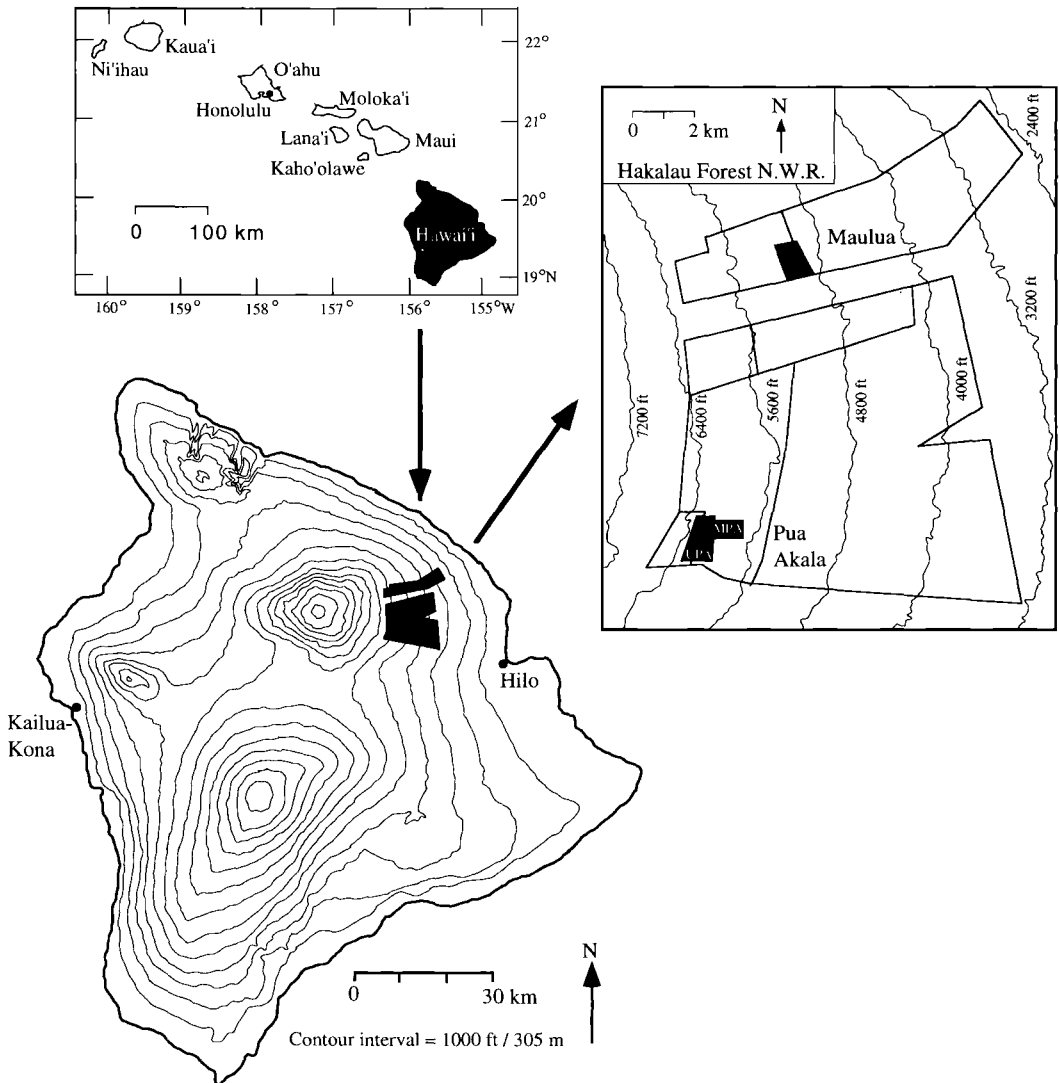


FIGURE 1. Location of three study sites (shown in black) at Hakalau Forest National Wildlife Refuge on Hawai'i Island. MPA = middle Pua 'Akala at 1,800 m elevation, UPA = upper Pua 'Akala at 1,900 m elevation, and Maulua at 1,550 m elevation.

basic, second basic, and definitive basic (adult) plumages (VanderWerf 1998a). Adults are generally dominant over subadults, and subadults act as floaters until they acquire a territory. 'Elepaio occur in all three study sites at Hakalau, but, at the start of this study in 1994, population density was 49% lower at Maulua than in similar habitat at Pua 'Akala (E. VanderWerf, unpubl. data).

POXLIKE LESIONS

To measure prevalence of poxlike lesions at each site, I captured birds in mist nets and visually examined them for symptoms. I also collected a small blood sample from the ulnar vein of each bird to test for

malaria. "A presumptive diagnosis of avian pox can be made from the gross appearance of growths on body surfaces" (USFWS 1987:141). However, I did not clinically confirm the field diagnoses of avian pox in 'Elepaio because biopsy was judged to be too invasive and I did not want to exacerbate any lesions or deformities. I believe that avian pox is the most likely cause of the cutaneous lesions found in 'Elepaio at Hakalau. Other diseases, such as laryngotracheitis and trichomoniasis, can cause symptoms similar to those of the diphtheritic form of avian pox (van Riper and van Riper 1985, Tripathy 1993), and mites can cause lesions and warty growths typical of the cutaneous form of avian pox. I therefore assumed birds with cu-

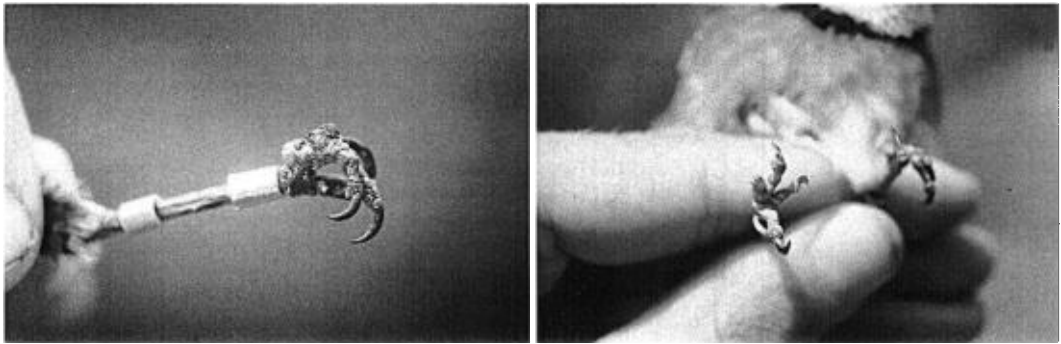


FIGURE 2. 'Elepaio feet with avian poxlike symptoms: left, active lesions; right, missing and deformed toes typical of healed lesions.

taneous lesions, wartlike growths, or soft swellings had active avian pox; those with missing or deformed toes had healed pox; and those with no external symptoms were healthy (Fig. 2). The timing of epizootics was determined by the cohorts of 'Elepaio having poxlike lesions, with ages of birds based on plumage. For example, birds that had first basic plumage in 1994 must have hatched in 1993, those with second basic plumage in 1994 must have hatched in 1992, and those with definitive adult plumage in 1994 must have hatched in 1991 or earlier.

DEMOGRAPHY

I monitored survival and reproductive behavior of banded birds on regular visits to each territory throughout the year. If a bird was not found in its traditional territory and another bird was found in its place, I assumed the original bird was dead. I believe this assumption is valid because 'Elepaio remain on their territory year-round and have extremely high territory fidelity in both sexes, approximately 97% (E. VanderWerf, unpubl. data). I made extensive searches of surrounding areas in all directions, but only twice relocated a bird that had disappeared from its territory. Because emigration was rare and the probability of resighting a bird that was alive and on the study area was reliably high (0.993; E. VanderWerf, unpubl. data), I calculated annual survival by enumeration

(Lepson and Freed 1995). I calculated reproductive success as the proportion of pairs fledging at least one chick. Only pairs I observed feeding fledglings were counted as successful. Fledglings are fed by their parents for at least a month, are easy to locate by their begging calls, and remain on their natal territory until chased away by the parents at the onset of the subsequent breeding season. I estimated population density at each site by converting the average territory size to numbers of birds/ha. This method thus estimates the breeding population because it includes territory holders and excludes nonbreeding floaters and juveniles. I mapped territories through observations of boundary disputes, and in some cases by playbacks (Falls 1981), and calculated territory size by the minimum convex polygon method using WILDTRAK (Todd 1992).

RESULTS

POXLIKE LESIONS IN 'ELEPAIO

Prevalence of poxlike lesions in 'Elepaio differed dramatically among sites at Hakalau ($\chi^2 = 25.3$, $df = 2$, $P < 0.001$). At both Pua 'Ākala sites combined, only one of 62 'Elepaio (1.6%) had poxlike lesions, but at Maulua 40% of 35 'Elepaio had poxlike lesions (Fig. 3). No 'Elepaio were captured with active lesions; all infected birds had deformed or missing toes. The deformities and healed lesions generally were not severe and did not appear debilitating. Most birds had from one to three deformed toes or claws, and a few had a slightly deformed foot. The most severe case observed was a bird that was missing most of two toes and had two other toes and claws deformed. No 'Elepaio were captured with large deformities on the feet, legs, or head. It is possible, however, that birds with more severe infections did not survive and died before this study began.

Prevalence of poxlike lesions in 'Elepaio at Maulua varied over time ($\chi^2 = 15.8$, $df = 1$, $P < 0.001$), which was revealed by the cohorts that contained infected birds. Seventy percent of birds that hatched in 1992 or earlier had healed

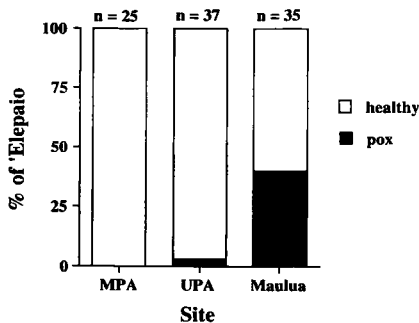


FIGURE 3. Incidence of avian poxlike lesions in 'Elepaio at three study sites in Hakalau Forest National Wildlife Refuge, Hawaii'i Island.

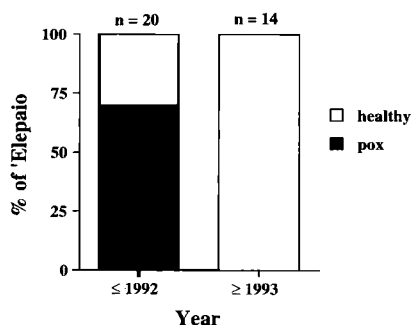


FIGURE 4. Incidence of avian poxlike lesions in 'Elepaio at Maulua over time.

lesions, but all birds hatched in 1993 or later showed no signs of lesions (Fig. 4). The population density of 'Elepaio at Maulua increased 65% during the study, from 0.66 birds/ha in 1994, to 1.03 in 1995, and 1.09 in 1996. Age structure of the breeding population at Maulua also changed over the same period, from 50% subadults in 1994, to 42% in 1995, and 8% in 1996. All new territory holders at Maulua were only one or two years old. Two 'Elepaio that were banded as juveniles in 1994 each obtained a territory and a mate in 1995 close to their natal territories. In contrast, at upper Pua 'Ākala, where habitat was similar to that at Maulua but where few birds had lesions, population density remained relatively constant from 1994 to 1996 (1.25–1.27 birds/ha), and the proportion of the breeding population consisting of subadults was consistently small (4–20%). By 1996, Maulua and upper Pua 'Ākala were similar in population density (1.09 versus 1.26 birds/ha, respectively) and in age structure (8% versus 4% subadults, respectively).

No birds with active lesions were caught, but survival of 'Elepaio with healed lesions (0.89, $N = 45$ bird-years) was very similar to that of 'Elepaio without lesions (0.87, $N = 47$ bird-years). Survival was independent of whether a bird was healthy or had healed lesions ($\chi^2 = 0.06$, $df = 1$, $P = 0.81$). Reproductive success at Maulua of pairs in which at least one bird had healed lesions (0.71, $N = 38$ pair-years) was similar to that in pairs with two healthy birds (0.62, $N = 29$ pair-years), and did not differ between these two groups ($\chi^2 = 0.60$, $df = 1$, $P = 0.44$). Whether or not a bird was infected was independent of whether its mate was infected ($\chi^2 = 1.63$, $df = 1$, $P = 0.20$).

DISCUSSION

Poxlike lesions were much more prevalent at Maulua than at either Pua 'Ākala study site, which probably at least partly explains the lower

population density of 'Elepaio found at Maulua in previous surveys (Scott et al. 1986) and at the start of this study. The cohorts of 'Elepaio with poxlike lesions indicated higher infection rates at Maulua in 1992 that decreased by spring 1993. Prevalence of deformed birds at Maulua was very high with 70% of birds missing digits. Population density apparently was greatly reduced in 1992, but increased rapidly and by 1996 had returned to a level similar to that at upper Pua 'Ākala, where there was no evidence of lesions. When population density was low at Maulua, many young birds were able to acquire territories and breed, but as the population recovered and density increased, most subadults were excluded from the breeding population and acted as floaters, as seen each year at Pua 'Ākala. The differences in demography and population dynamics between Maulua and Pua 'Ākala and the recovery of the Maulua population provide strong circumstantial evidence that avian pox caused the low density of 'Elepaio at Maulua. Additional factors currently being investigated that also may be partly responsible for the lower population density at Maulua include habitat structure and arthropod abundance.

Higher disease prevalence at Maulua may also be responsible for the low densities of other bird species, such as Hawai'i 'Ākepa (*Loxops c. coccineus*), Hawai'i Creeper (*Oreomystis mana*), and 'Ākiapōlā'au (*Hemignathus munroi*; Scott et al. 1986). These endangered honeycreepers may be more susceptible than 'Elepaio to introduced diseases like malaria and avian pox, making them more vulnerable to local extinction. Below I discuss the implications of these findings for the importance of poxlike lesions in reducing Hawaiian forest bird populations in general and at Maulua in particular.

Poxlike lesions were probably more prevalent at the Maulua study site because the site is at a lower elevation than the Pua 'Ākala study sites (1,550 versus 1,800–1,900 m). In other areas of the island of Hawai'i, van Riper et al. (1986) demonstrated that the proportion of birds with malaria was lower at high elevations, with almost no infected birds above 1,600 m. Goff and van Riper (1980) found that the upper-elevation limit of *Culex* mosquitoes was 1,500 m in most months, but occasionally up to 1,650 m. In this study, poxlike lesions were common at 1,550 m elevation at Maulua in some years, but very rare at 1,800–1,900 m at Pua 'Ākala, demonstrating a consistent upper limit to the distribution of disease in different areas of the island. The similar upper-elevation limits of poxlike lesions and mosquitoes suggest that mosquitoes may be the primary vector of avian pox among Hawaiian forest birds. Incidence of poxlike le-

sions also was independent between mates, which would not be expected if transmission occurred primarily by contact with an infected bird, perch, or nest.

Elevations from 1,500–1,600 m may be especially important and demographically interesting due to the dynamic nature of disease prevalence and transmission (Atkinson et al. 1995). Contact between native birds and disease vectors is most frequent at these elevations, but abundance of vectors and thus of disease transmission may vary among seasons (van Riper et al. 1986) and among years (this study), resulting in periodic epizootics of disease separated by varying lengths of time. Recovery of the 'Elepaio population at Maulua was rapid in this case and required only four years, but the frequency of epizootics is unknown and could have important effects on persistence and variation in size of bird populations. If epizootics are infrequent, populations of most bird species may fully recover between disease episodes, and populations may be large most of the time. If epizootics are frequent, population sizes may be smaller and below carrying capacity much of the time, and species that are highly susceptible may have insufficient time to recover between disease episodes, resulting in ever-dwindling populations and eventual extinction. Species that are somewhat more resistant, perhaps such as 'Elepaio, may be able to maintain larger populations during epizootics, and their population remnants would recover more quickly. Whether a particular species can persist in an area thus may depend on the interaction between frequency of epizootics and susceptibility to disease of that species. Recovery also may be more rapid in areas with less habitat disturbance because population remnants are larger or closer together.

'Elepaio may be more dispersive and better able to recolonize vacant habitat than the endangered Hawai'i 'Ākepa and Hawai'i Creeper because of their life histories. Both 'Elepaio and these honeycreepers have high site fidelity as adults (VanderWerf 1998a, Woodworth et al. *this volume*), but young 'Elepaio may be forced to disperse more often than young honeycreepers because the highly territorial nature of adult 'Elepaio forces young birds to search for vacant space (VanderWerf 1998a). The honeycreepers are less territorial, and young birds may have more opportunity, and may prefer, to return to their natal area to breed (Lepson and Freed 1995, VanderWerf 1998b, Woodworth et al. *this volume*).

If an 'Elepaio can survive initial infection, its future survival and ability to reproduce are not affected. Such birds probably also develop a greater degree of immunity to subsequent infec-

tions by the same pathogen (Karstad 1971a,b; Tripathy 1993). Mortality rate among birds with active infections could not be measured in this study, but on O'ahu preliminary evidence indicates annual mortality of 'Elepaio with active poxlike lesions is quite high, approximately 40% (VanderWerf et al. 1997; E. VanderWerf, unpubl. data). Birds with mild infections, in which only the toes are affected, frequently recover, and loss or deformation of a few toes does not appear to be debilitating. More severe infections of the feet, legs, and head often may lead to mortality. No 'Elepaio with large healed lesions on the feet, legs, or head were captured in this study. If certain populations or individuals are discovered to have greater immunity to avian pox, these should be selected for use in any captive breeding efforts. In particular, captive breeding and reintroduction have been proposed as conservation measures for the O'ahu 'Elepaio (Ellis et al. 1992a). Use of disease-resistant birds could greatly increase the success of reintroductions and thus the value of captive breeding, and this issue should be investigated before any captive breeding is begun.

Vaccines against some forms of avian pox have been developed, primarily for use in the poultry industry, but vaccination of wild bird populations against poxvirus probably is not a practical long-term conservation strategy. Birds must be captured in order to be vaccinated cutaneously, which is the most effective method (Nagy et al. 1990). Mass inoculation of wild birds through vaccines in food supplements or drinking water cannot ensure that birds obtain an adequate immunogenetic dose and is potentially dangerous because it may select for resistant forms of the virus. Immunogenicity of vaccines also varies considerably among viral species (reviewed in Tripathy 1993) and it is not known which or how many species of avian pox occur in Hawai'i. Furthermore, immunity acquired through vaccination may provide some short-term protection for very young offspring via maternal antibodies, but it will not be heritable and will not provide long-lasting protection. The effort and cost required to continually capture and vaccinate generation after generation of wild birds is likely to be prohibitive. A more practical approach may be to limit transmission of avian pox by controlling the primary vector, mosquitoes, or to identify naturally resistant populations or individuals.

Ideally, it would be best to control vectors year-round to maximally reduce disease transmission. In reality, funding for vector control is likely to be limited, and managers will have to choose when and where to apply vector control so that it is most effective, and this decision

should be based on several factors. There is accumulating evidence in birds that nutritional limitation causes a trade-off between reproductive effort and ability to resist parasitic infection (Gustafsson et al. 1994), resulting in greater susceptibility to disease during times of stress, such as egg production (Allander and Bennett 1995, Oppliger et al. 1996) and feeding of nestlings (Norris et al. 1994, Richner et al. 1995). On the other hand, rate of disease transmission is likely to be influenced by vector abundance, resulting in higher disease prevalence when vectors are more common (van Riper et al. 1986). In areas of Hawai'i where mosquitoes are common year-round, such as low elevations forests on O'ahu, vector control might be most effective at reducing the effects of disease during the spring breeding season when birds are stressed by producing eggs, incubating, and feeding offspring. At higher elevations, perhaps such as Hakalau, or in drier areas where mosquito populations vary seasonally with temperature and rainfall, vector control might be most effective in fall and winter when mosquito abundance peaks (Goff and van Riper 1980).

In addition to Hakalau, poxlike lesions have been found in 'Elepaio at Hawai'i Volcanoes National Park, Manukā Natural Area Reserve, and Pōhakuloa Training Area on Hawai'i Island, on the Alaka'i Plateau on Kaua'i, and in many areas of O'ahu (Herrmann and Snetsinger 1997, VanderWerf et al. 1997; C. Atkinson, pers. comm.; E. VanderWerf, unpubl. data). Poxlike lesions are widespread and very common in some areas, and avian pox may be reducing many 'Elepaio populations, making it one of the most important threats to this species.

The results of this study further illustrate the importance to native Hawaiian birds of high-elevation forests as refuges from mosquito-borne diseases. Populations of 'Elepaio at Pua 'Ākala from 1,800–1,900 m elevation were dense, stable, and relatively unaffected by disease during this study. However, prevalence and distribution of vectors and disease vary from year to year (van Riper et al. 1986), and bird populations at

elevations above the usual "mosquito zone" may occasionally be at risk. Maulua had no disease and presumably few mosquitoes in most years, but periodic epizootics may be sufficient to make populations of sensitive bird species fluctuate dangerously at Maulua. Upper Pua 'Ākala at 1,900 meters likely is subject to disease very infrequently, but a few 'Elepaio were infected even there, indicating small numbers of mosquitoes occasionally reach even that high elevation. Much as civil engineers must deal with "100-year floods," avian conservation biologists in Hawai'i should consider the eventuality of a "100-year epizootic" that would affect populations of forest birds at elevations traditionally considered safe from disease. Such an event could be catastrophic and would be difficult to contend with, but development of safe, practical methods of mosquito control would be extremely valuable in reducing the severity of any epizootic. Additional management techniques such as removal of feral pigs to reduce mosquito breeding habitat, removal of introduced predators like roof rats (*Rattus rattus*) and cats (*Felis catus*) to increase nest success, and habitat restoration to increase food supply, population size, and range may help by relieving other potential threats so recovery can be as rapid and complete as possible following the epizootic.

ACKNOWLEDGMENTS

This research was supported by grants and awards to E. VanderWerf from the Ecology, Evolution, and Conservation Biology Program of the University of Hawai'i, the ARCS Foundation, Sigma Xi, the Hawaii Audubon Society, and by a grant from the MacArthur Foundation to L. Freed, R. Cann, and S. Conant. I thank the staff of Hakalau Forest National Wildlife Refuge, especially refuge manager R. Wass and refuge biologist J. Jeffrey, for permission to work and logistical help. Valuable field assistance was provided by J. Bennett, M. Burt, M. Ono, and J. Rohrer. T. Yoshikawa and K. Asoh helped with histological preparations. The manuscript was improved by comments from S. Conant, L. Freed, A. Taylor, and C. van Riper. I greatly benefited from discussions about disease in Hawaiian birds with C. Atkinson, R. Cann, L. Freed, S. Jarvi, D. LaPointe, B. Nielsen, and C. van Riper.