

A THREE-LEGGED AFRICAN PENGUIN *SPHENISCUS DEMERSUS*

RALPH ERIC THIJL VANSTREELS^{1,2}, NOLA J. PARSONS³ & PIERRE A. PISTORIUS^{1,2}

¹Marine Apex Predator Research Unit, Institute for Coastal and Marine Research,
Nelson Mandela University, Summerstrand 6031, Port Elizabeth, South Africa (ralph_vanstreels@yahoo.com.br)

²DST-NRF Centre of Excellence at the FitzPatrick Institute of African Ornithology, Department of Zoology,
Nelson Mandela University, Summerstrand 6031, Port Elizabeth, South Africa

³Southern African Foundation for the Conservation of Coastal Birds (SANCCOB), Table View 7441, Cape Town, South Africa

Received 31 October 2017, accepted 16 November 2017

ABSTRACT

VANSTREELS, R.E.T., PARSONS, N.J., PISTORIUS, P.A. 2018. A three-legged African Penguin *Spheniscus demersus*. *Marine Ornithology* 46: 23–26.

We report the case of an adult African Penguin *Spheniscus demersus* with a supernumerary hindlimb. It was located between the left foot and the tail, and the penguin was able to move this third leg and foot as a response to being handled. However, the breadth of movement was very limited, and the leg was not functional. The bird had fully developed ovaries and was in good body condition, indicating the additional limb did not hinder survival to sexual maturity.

Key words: African penguin, deformity, malformation, South Africa, Southern Hemisphere, supernumerary limb

INTRODUCTION

Physical deformities have been occasionally reported in penguins (Voisin *et al.* 2002, Raidal *et al.* 2006, Buckle *et al.* 2014, Jones *et al.* 2015), although supernumerary limbs are rare. Voisin *et al.* (2002) reported finding the carcass of a large King Penguin *Aptenodytes patagonicus* chick with a third foot on 28 April 1966 at Possession Island, Crozet Archipelago. The third foot was described as “small and appended to its right thigh; it had only two digits.” Unfortunately, the specimen was in an advanced stage of decomposition, precluding further analysis.

To our knowledge, the only other published case of a penguin with supernumerary limbs involves a Magellanic Penguin *Spheniscus magellanicus* chick found in summer 2012/13 with two additional flippers at Punta Tombo, Argentina (TPP 2013). The supernumerary flippers were poorly developed, attached under the normal flippers, and approximately 60% of their length. Rubber bands were placed around the abnormal flippers, causing them to fall off after a few weeks, and the chick was reported to have fledged successfully. We provide the first record of a supernumerary limb in an African Penguin *Spheniscus demersus*, and discuss the potential causes and conservation implications.

CASE REPORT

On 6 December 2010, an adult African Penguin was found ashore at Stony Point, South Africa (34°22'27"S, 18°53'43"E), and was brought to the Southern African Foundation for the Conservation of Coastal Birds (SANCCOB). Upon veterinary examination, a severe wound was noted on the left tarsal joint, apparently caused by a watercraft propeller. The tendons, ligaments, and joint capsule had been gravely compromised; the bones and joint were exposed; and the wound was heavily contaminated. Considering the poor prognosis and the intense pain presumably experienced by the

bird, the decision was made to euthanize it. Before its death, a supernumerary foot was noted between the left foot and the tail. The penguin was able to move this limb as a response to being handled; however, the breadth of movement was very limited and the leg was not functional.

Post mortem examination revealed that the supernumerary limb was relatively small (length 6.9 cm, width 3.2 cm, height 2.1 cm), and, in its natural position, it remained barely noticeable, hidden behind the left foot, aligned perpendicularly to the main axis of the body (Fig. 1). The external appearance mimicked that of a normal foot, with feathered skin on the proximal area transitioning to scaly skin on the extremity. The most evident external difference was the lack of clearly defined digits, although the bumps and grooves on the distal part of the foot resembled digit-like structures. Dissection revealed that the bone structure of the anomalous limb was a miniature and deformed version of a normal leg (Fig. 2). The bones were fused into a single unit, with parts corresponding to bones of the pelvis (ilium/ischium) and of a complete leg (from femur to digits). Large areas of osteolysis and osteosynthesis were juxtaposed, especially in the bones that corresponded to the junction of the tibiotarsus and the tarsometatarsus. The proximal part of the limb was not articulated with the rest of the penguin's skeleton, but instead was encapsulated within a fibrous capsule. This pseudo-joint was loosely attached to muscle and soft tissue in the area between the pubis and the pygostyle/caudal vertebrae, caudal to the left ischium. Deformed muscles, tendons, cartilage, and conjunctive tissue accompanied the anomalous limb, in a disorganized version of the soft-tissue architecture of a normal leg.

Besides the supernumerary limb and the lesion to the left foot that motivated the euthanasia, the penguin was found to be generally healthy and had no other significant pathological findings on necropsy. The bird was in excellent body condition (body mass 2.96 kg; score 4 in the scale proposed by Clements

& Sanchez 2015), with well-developed chest musculature and abundant stocks of subcutaneous (maximum thickness 8.2 mm) and perivisceral fat. It was a female, and its ovary was well-developed (largest follicle diameter 2.8 mm); it was thus presumed to be sexually mature, hence at least four years of age or older (see Williams 1995).

DISCUSSION

Supernumerary limbs result from abnormalities in the development of the limb buds. In chickens, after as little as 50–55 h of incubation, limb formation begins in the form of limb buds, which are slightly

thickened ridges of the somatic lateral plate mesoderm. These limb buds differentiate into wing and leg buds at 4.5 d. Then the ectoderm of the tip of the limb bud becomes thickened, forming the apical ectodermal ridge at 6 d. This ridge plays a key role in limb development, which will be halted if this ridge is surgically removed. On the other hand, supernumerary limbs may develop if an additional ectodermal ridge is surgically grafted (Bellairs & Osmond 2014). Therefore, the formation of a supernumerary limb in the studied bird was probably related to abnormalities in the development of the apical ectodermal ridge during the early incubation period. The embryology of the African Penguin has yet to be studied; however, studies in Gentoo Penguins *Pygoscelis*




Fig. 1. External appearance of the supernumerary limb of an African Penguin: (a) full body view, (b) left side, (c) ventral side, (d) oblique close-up of the dorsal surface, (e) oblique close-up of the plantar surface.

papua have revealed that wing and leg buds are first visible after 12 d of incubation (Waterson & Geddes 1909).

Whether the supernumerary limbs observed in penguins in this and previous studies were caused by intrinsic (e.g., random genetic mutations, problems in embryological development) or extrinsic factors (e.g., endocrine disrupting chemicals, nutritional stress) remains an open question. However, the scarcity with which they have been reported (this was the only case recorded at SANCCOB from more than 15 000 African penguins admitted for rehabilitation since 2001) suggests that supernumerary limbs are an incidental finding and probably do not represent a significant conservation threat at present. Nonetheless, carefully recording of these and other physical abnormalities may be instrumental to develop long-term historical time-series. Such time-series allow for the detection of unusual patterns relevant to conservation. Such patterns can lead to addressing their underlying causes, such as pollution, disease,

or dietary or genetic problems. An example is the study by Buckle *et al.* (2014) documenting an abrupt increase in craniofacial deformities in endangered Yellow-Eyed Penguins *Megadyptes antipodes* at a single breeding site in New Zealand, which alerted researchers to the possibility of local contamination by a teratogen.

Perhaps the most surprising fact about the penguin examined in this study is that it survived into adulthood, and was sexually mature and in excellent body condition at the time of its death. This may have been possible because penguins rely primarily on their forelimbs for aquatic locomotion, and because the bird could compensate for any drag effect produced by the supernumerary leg.

ACKNOWLEDGEMENTS

We wish to thank the many staff, collaborators and volunteers at SANCCOB, especially Venessa Strauss and Katrin Ludynia.

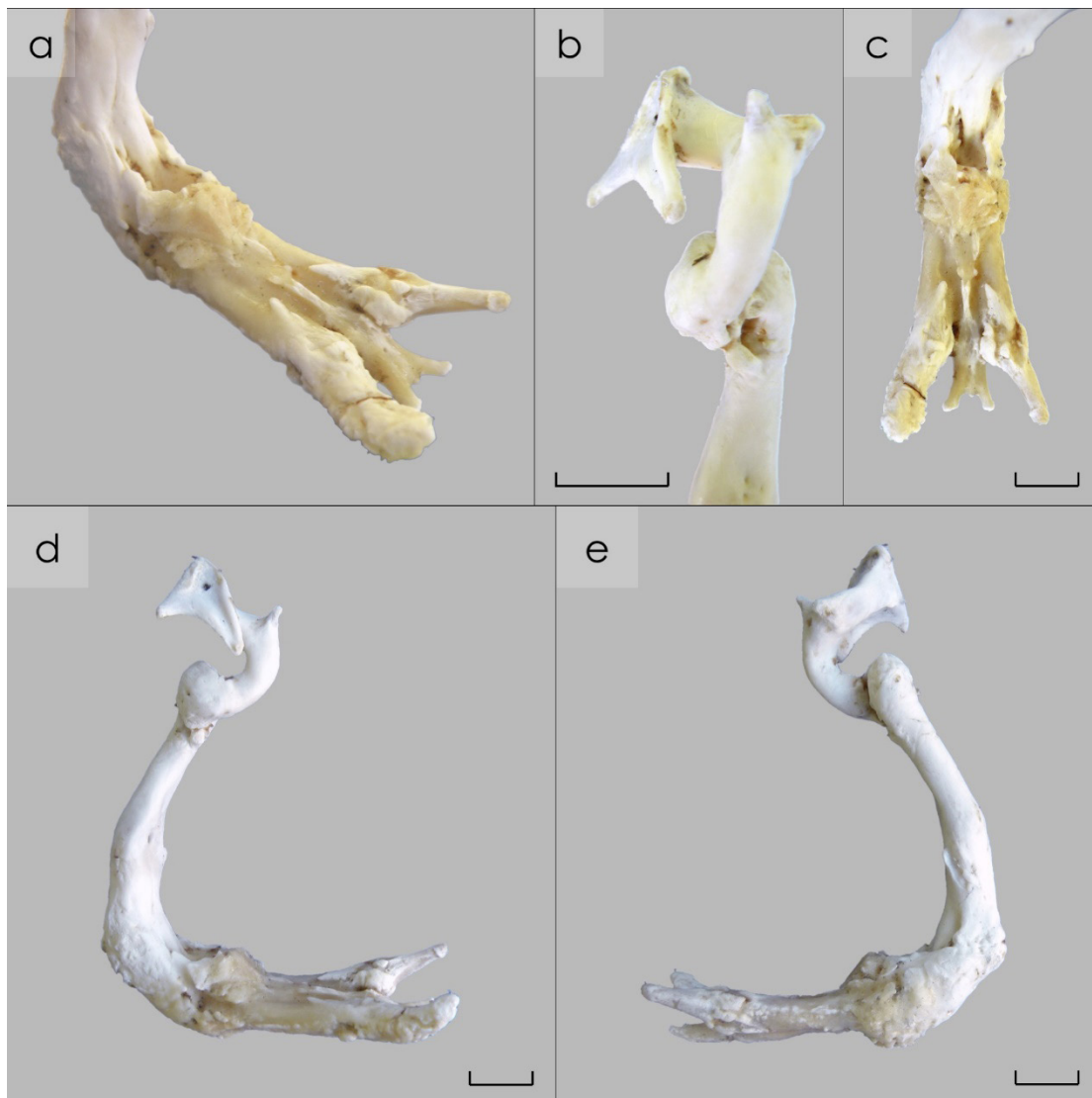


Fig. 2. Bone structure of the supernumerary limb of an African Penguin: (a) oblique angle, (b) ventral view of the proximal extremity, (c) dorsal view of the distal extremity, (d) medial side (right), (e) lateral side (left). Scale bars represent 1 cm.

SANCCOB is supported by a wide range of donors, including the International Fund for Animal Welfare (IFAW), Hans Hoheisen Charitable Trust, National Lottery Distribution Trust Fund (NLDTF), Sea Research Foundation (Mystic Aquarium), and Georgia Aquarium. This research was supported by the National Research Foundation. Christopher Jones and an anonymous reviewer provided helpful comments to improve our presentation.

REFERENCES

- BELLAIRS, R. & OSMOND, M. 2014. *The Atlas of Chick Development*. Oxford, UK: Academic Press.
- BUCKLE, K.N., YOUNG, M.J. & ALLEY, M.R. 2014. Investigation of an outbreak of craniofacial deformity in yellow-eyed penguin (*Megadyptes antipodes*) chicks. *New Zealand Veterinary Journal* 2: 250-257.
- CLEMENTS, J. & SANCHEZ, J.N. 2015. Creation and validation of a novel body condition scoring method for the Magellanic Penguin (*Spheniscus magellanicus*) in the zoo setting. *Zoo Biology* 34: 538-546.
- JONES, C.W., RISI, M.M., KUNTZ, W., RYAN, P.G., STEINFURTH, A. & BOND, A.L. 2015. Bill deformities in penguins (Spheniscidae): A global review. *Marine Ornithology* 43: 207-209.
- THE PENGUIN PROJECT (TPP). 2013. *Spring/summer 2013 Penguin Project update*. [Available online at: http://www.penguinstudies.org/wp-content/uploads/2014/09/2013_Spring_Update.pdf. Accessed 10 May 2016].
- RAIDAL, S.R., SHEARER, P.L., CANNELL, B.L. & NORMAN, R.J.B. 2006. Micromelia in Little Penguins (*Eudyptula minor*). *Journal of Avian Medicine and Surgery* 20: 258-262.
- VOISIN, J.-F., MOUGIN, J.-L., SEGONZAC, M. & ROPERT-COUDERT, Y. 2002. Colour aberrations and physical deformities in the King Penguin *Aptenodytes patagonicus* at the Crozet Islands. *Marine Ornithology* 30: 1-4.
- WATERSTON, D. & GEDDES, A.C. 1909. Report upon the anatomy and embryology of the penguins collected by the Scottish National Antarctic Expedition. *Transactions of the Royal Society of Edinburgh* 47: 223-244.
- WILLIAMS, T.D. 1995. *The Penguins — Spheniscidae*. Oxford, UK: Oxford University Press.